

NIH LIBRARY TRANSLATION (NIH-81-109)

J Psychol Neurol 51 (1/2):1-56 (1942).

THE FINER ANATOMY OF THE SEPTUM AND OF THE STRIATUM
WITH 72 ILLUSTRATIONS

BY

Harold Brockhaus

From the Institute of the German Brain Research Association, Neustadt
im Schwarzwald (Director: Prof. O. Vogt)

CONTENTS

Introduction

Preliminary remarks: Material and technical data

Results

I. The Gray Masses of the Septum.

Discussion of the results

II. The Striatum

a) Fundus striati

Supplement:

1. Insulae olfactoriae striatales

2. The cortex of the Tuberculum olfactorium

3. Nucleus subcaudatus

b) Nucleus caudatus

c) Putamen

Discussion of the results

Summary

Literature

INTRODUCTION

It is the purpose of this publication to investigate, more thoroughly than done before, the structure of the gray masses of the septum¹ and striatum (as interpreted by C. and O. Vogt, Spatz and others), using cyto and myelo-architectonic methods. It is not customary in general to study both fields jointly, as done in this publication. When doing so here, it was intended to clarify recurrent opinions voiced in earlier and recent literature on the more or less close morphogenetic, structural and thereby possibly also functional correlations between these two fields of between parts of the latter (by means of a study focused on the finer structural conditions within this area in the mature human and primate brain) (Maynert, Kappers, Johnston, Kuhlenbeck, Rose, among others). Moreover, the gray masses of the septum and striatum are to be studied, principally in the oral area of the latter (N. accumbens, Ziehen), generally believed so far to originate from the encephalon. The structural correlation between the above and the ventral and ventrocaudal adjoining prothalamatic nuclei is to be investigated² which, in a wider sense, belong to the hypothalamus and therefore to the mid-brain. It is to be clarified how the latter behave and how far they differ structurally. Admittedly, a final answer to the question will be available only after termination of a study (now under preparation) concerning the finer structure of the hypothalamus.

¹ Septum is always interpreted here as the ventral (phylogenetically ancient) sector, containing nerve cells and nerve fibers, and therefore characterized by a thick wall. The Septum pellucidum, on the other hand, extends dorsally between this part and the corpus callosum fibers; it developed physogenetically at a later date (Kappers), as a result of commissural plate growth, mainly the growth of the corpus callosum in sagittal direction (Hochstetter) It is nearly free from N_z (nerve cells) and has few nerve fibers; it is therefore definitely thin-walled.

² The term prothalamus (from the Greek $\pi\rho\theta\omicron$ - - lat. prae-) originates from "N. praethalamici" used by Winkler and Potter (1914). It is used here instead of the term "preoptic area" which we consider less suitable (Rioch, Papez, Crouch, etc.). The definition, mainly used in American literature, has, in our opinion, to be rejected because the essential structure in an area in low vertebrates named N. preopticus magnocellularis does not correspond to the oral sector of the N. basalis (N. substantiae innominatae) as Loo, Papez and other contend Instead, numerous investigations definitely indicate (Scharrer, etc.) that it corresponds to the N. supraopticus and

The investigation focused on the human brain and on the brain of some mammals, in particular of primates. On the one hand, the author intended to confirm findings in closely related and therefore comparable species regarding finer structural conditions; on the other hand, the study focused on specific progress in the human field.

PRELIMINARY REMARKS

Material, Technical Data:

A 58. Male, 24 years old, normal. Frontal section series. Dextral hemisphere. Formol fixing. Embedded in paraffin. Section thickness 20 μm . Cell staining with Cresyl violet according to Nissl, fiber staining according to Heidenhain (modified).

A 43. Male, 30 years old, normal. Dextral hemisphere. Same treatment.

A 37. Male, 37 years old, normal. Sinistral hemisphere. Formol fixing. Muller's staining; section thickness 40 μm ; medullary sheath staining according to Kultschitzky.

Used for control: frontal section series A 56 and A 61, as well as the horizontal section series A 66. All illustrations appear to represent sections of the sinistral hemisphere, i.e., they show the mirror image of dextral hemisphere sections.

The numerals in surveys and diagrams (Figures 53-71) refer to illustrations in which the localizations at issue are represented with stronger magnification. When a small cross appears to the right on top of such a numeral (for example: 30), it indicates that the illustration originates from a section located at a maximal distance of 1.3 mm orally or caudally from the corresponding general survey.

paraventricularis. In higher mammals, the structure at issue was always defined as belonging to the hypothalamus in a stricter sense, and even American authors did not include it in their preoptic area.

ABBREVIATIONS

A.d	Ncl. amygdalae dorsalis (Supraamygdaleum)	prp	Subregio claustralis praepiriformis
A.v	Ncl. amygdalae ventralis (Am. proprium)	Pt	Putamen
B	basal nuclear complex	Pt.c	Putamen caudale
C.a	Commissura anterior	Pt.l	Putamen laterale
C.i	Capsula interna	Pt.li	Putamen limitans
C.sf	Comm. subfornicalis	Pt.m	Putamen mediale
Cd	Ncl. caudatus	Pt.v	Putamen ventrale
Cd.l	Ncl. caudatus lateralis	Pth	Prothalamus (preoptic area)
Cd.m	Ncl. caudatus medialis	RA	Regio Ammonis
Cl	Clastrum	S	Septumgrau
F	Fornix	S.if	Ncl. interformicatus septi
Fu	Fundus striati	S.pc	Ncl. parvocellularis septi
Fu.cd	Fundus caudati	sc	Ncl. subcaudatus
Fu.pt	Fundus putaminis	Sf	Ncl. septofornicatus
Fu.sv.l	Fundus subventricularis lateralis	Sf.d	Ncl. septofornicatus dorsalis
Fu.sv.m	Fundus subventricularis medialis	Sf.v	Ncl. septofornicatus ventralis
G.l	Corpus geniculatum laterale	St.t	Stria terminalis
H	Hypothalamus	Sv	Ncl. septoventricularis
I.o.s	Insulae olfactoriae striatales	T	Thalamus
II	Tractus opticus; Chiasma opticum	T.o	Tuber (Trigonum) olfactorium
Pal	Pallidum	V	lateral ventricle

Other abbreviations, used in the text only:

Ef	single fibers	Nz	neurons
Fb	fiber bundle	Spz	spindle cell, fusiform cell
Gf	principal fibers, basic fiber network ("Grundfasern")		

RESULTS

I. The Gray Masses of the Septum

In the structure macroscopically designated as the *Septum* in man, a discrimination must be made between two fundamentally different parts: the medial and the lateral part.

A third part, still localized in the ventrolateral *Septum* in lower primates (*Lemur catta*), no longer encircles in man the lower ventricle angle, or encircles it to a very minor extent only, toward the median; therefore, it does no longer represent a true topographical *septum gray*. This condition admittedly seemed initially ontogenetic and developed later in the mature brain into the still visible adhesion of the lower surface sectors of the ventricle angle (see figure 21). the structure at issue, correctly defined by Kappers as belonging to the striatum, is the medial component of *N. accumbens* (Ziehen, 1908; Marsupals). It will be described in correlation with the striatum (see p. 17 of German text).

The medial component (large celled, deep layer, Shimazono, 1912), in part the *N. hyperchromaticique du septum* of Foix-Nicolesco, does not represent a true Septum structure either. In man, it forms the most orodorsal branch of *N. basalis* in Koelliker's demarcation. Despite the fact that it differs structurally from the principal laterocaudal component of this nucleus, I include the latter - jointly with Kryspin-Exner (1922) - with the lateral and other related components, in the wider definition of "*basal nuclear complex*". A subsequent report will describe this component in correlation with other parts of said complex.

Accordingly, the true septum gray is exclusively represented by the lateral component in the vicinity of the ventricle (Shimazonos, lateral, small-celled and intermediate average-sized cell layer).

Comparative anatomic investigations were conducted in this field in reptiles and low mammals, mainly by Kappers and Theunissen (1908), Herrick (1910), Johnston (1913, 1917, 1923), Crosby (1917), Loo (1931), etc. These studies revealed that findings of earlier experiments, according to which this brain wall sector is definitely a cortex component (Meynert, Koelliker, Shimazono), are not acceptable in its original form. The last test of this type was performed by M. Rose (1927), who described the gray of the *septum* as a specific sector of its *cortex semiparietinus s. striatis* (see also below, page 27 of German text).

Johnston (1913) was first to specify this area in reptiles and lower mammals with the aforementioned method, which leads to the conclusion that said area corresponds to areas in primates and in man. The area named by this author *Primordium hippocampi* very probably corresponds to the gray at issue here, both regarding its delimitation proportionately to other areas and, in part also, regarding its subdivisions. However, other definitions, most of which fail to take the structure into exact consideration, always include other aforementioned areas as well: *precommissural body*, El. Smith (1903); *A. praecommissuralis septi*, Kappers and Theunissen (1908); Rothig (1909); *N. medianus* and *lateralis septi*, Herrick (1910); *A. parolfactoria*, Johnston (1915); *N. parolfactorius medialis* and *lateralis*, Crosby (1917). Regrettably, the definition *Primordium hippocampi* is unfortunate from several viewpoints: on the one hand, this area has nothing in common with the hippocampus formation. It does by no means represent a "preliminary stage" in this respect (see also the criticism of Darts, 1920). On the other hand, the term

Primordium hippocampi was used by Johnston (1915) and Crosby (1917) to describe a more dorsal localized structure, not associated with the hippocampus formation. This however is unrelated with the definition used in 1913.

At variance from the aforementioned authors, Loo (1931) described the subdivision of the area at issue here more specifically in the opossum brain. His *N. septalis medialis*, as does the *N. medianus septi* of Herrick, defines the aforementioned most orodorsal branch of the "*basal nuclear complex*". However, his *N. sept. dorsalis* describes the central cavity gray (*Höhlegrau*) belonging to the *prothalamus*. On the other hand, his *N. septalis lateralis* and his *Pars dorsalis* and *ventralis*, his *N. septalis fimbrialis* and *triangularis* are components of the true septum gray. Unfortunately, the diagrammatic representations are not suitable for accurate comparison. Whenever such a comparison is feasible, it is indicated in the text.

Intending to discriminate more specifically between components localized in the septum, but belonging to other larger complexes, I defined the area to be described below as the *true septum gray* (*N. septi proprius*, *S*).

Cytoarchitectonically, the *septum gray* is characterized by the predominance of an average to small-sized spindle cell type; its density diminishes in ventral to dorsal direction.

The myeloarchitectonic pattern shows minor content of single fibers. The paucity of single fibers in the medial parts is partially concealed by large masses of fibers (*Fornix longus*, fibers of the *diagonal band*, Broca).

Figure 1, with minor magnification, shows the survey of a section on which most nuclei of the *septum* are found. The largest dorsolateral part is occupied by a gray which I defined as *N. septoventricularis* (**Sv**), because it is located at the ventricle wall. Ventrally, a thick cell mass follows, for which I propose the name *N. septofornicatus* (**Sf**), also on account of its characteristic position (Figures 62-64 more clearly show the constant position of this area, which is immediately lateral, as related to the Fornix). The small-cell nucleus of the septum (*N. parvocellularis septi*, **S.pc**) comes next, localized more ventrally and laterally, at the wall of the lateral ventricle. The last of the septum nuclei identified by me (*N. interforficatus septi* (**S.if**)) is located more caudally. and is not visible on the section,(see p. 11 of German text). The medial component of the septum, belonging to the basal complex, is located medially from the *septoventricularis* and *septofornicatus*. This also includes a narrow, mostly large-cell group, ventromedially from **S.pc** (dotted boundary line). A sector to be considered as belonging to the *Prothalamus* (*preoptic area*; **Pth**) is located between the last-mentioned group and the medial component of **B**. To the left below, a small piece of the Striatum (*N. accumbens*; **Fu**) is found, separated by the cell-deficient zone **S.pc**.

Figure 2 shows the same area on a section situated somewhat farther caudally; it represents the fiber pattern in another brain. The dorsolateral position is the same, but **Sv** is smaller. **Sf** is extended in dorsoventral direction, in typical lateral position relatively to the Fornix fiber system; its lateroventricular part shows definitely delimited fibrous texture and it is rich in fibers dorsally as well. As in Figure 1, **S.pc** is positioned lateroventrally on the ventricle wall. Fornix fibrous tissues are located medially from these areas; the medial parts are also infiltrated by **S**. The *Fornix longus* is located dorsally in front of all fibers; the *Fornix inferior* is located ventrally from the maximally oral bundles. A piece of the striatum is visible to the left below here as well.

N. septoventricularis (Sv)

Location (Figures 1, 2, 58-65): **Sv** occupies most of the septum orally (Figures 58-59). It is thereby medially delimited first by the still thin *Fornix longus*; more caudally, it is delimited by part of the *N. septofornicatus*. Laterally, **Sv** always extends to the ventricle, separated from the latter by a fiber lamella of minor density and by the ependyma lining. Orally, it extends to the medulla of the *G. olfactorius medialis*, then penetrates the latter ventrally to some extent (Figure 58). Caudally, **Sv** passes over the Monroi foramen while always located dorsolaterally from the Fornix inferior (*Pars supraforaminalis* or *fimbrialis*, Rothig Kappers; part of the *N. septalis fimbrialis* according to Loo). It extends almost to the point where, at the bottom surface of the corpus callosum, the fornix columns separate once more, in lateral direction.

Cytoarchitecture (C, Figure 3): Average-sized³ Spz with large, oval nuclei, light yellow cell body and largely colored processes, mainly in lateral direction corresponding to the trend of the fibers (Figure 1). A narrow layer is found near the ventricle surface, in which neurons occur sporadically; they are smaller. This phenomenon is more pronounced in the caudate nucleus (see Figure 33). In the zone next to the cell-deficient layer, darker, slightly smaller and more polygonal neurons are frequently found. The glia is medially abundant in the area with maximal fiber density (Figure 2); it is more abundant here than laterally. Glia abundance is definitely more orally.

Myeloarchitecture (M, Figure 2): Medullary deficiency ("markarm"). Besides fine Gf, extending mainly in dorsoventral direction, less numerous, rougher single fibers are found in more lateral-sagittal direction. Both fiber types form a lamella (l) with minor density toward the ventricle. Fibers increase also toward the *Fornix longus* (infiltrating fibers?). Orally,

³ Dimensional data of course always refer to conditions in the areas at issue. For example, as compared with the brain cortex and most areas of the thalamus, the Nz of the septum gray and all small striatum cells must definitely be described as "small."

masses of relatively fine fibers appear, ventrally infiltrating from the direction of the *Gyrus subcallosus* and from the *G. olfact. med.* (fibers of the diagonal band of Broca and of the *medial olfactory stria (Riechwurzel)* (?); said fibers seem to terminate in this gray.

From the orally directed part (Figure 58) of the *G. olfactorius med.*, penetrating into the medulla, a not quite continuous cellular connecting bridge is always determinable; it forms a narrow cell band ventromedially from the striatum, to a medial, near-identically structured cell sector of the *N. olfactorius anterior* (Herrick, 1924; opossum). It is not reliably determinable whether this is a human remnant of a cell link between the medial components of the septum gray, as described by Crosby and Hymphrey in reptiles and mammals (1938). In the dog and in the rabbit, this cell bridge is determinable in continuous serial sections, up to the caudal, specially structured part of the *N. olfactorius anterior*.

No structural correlation of any kind exists between **Sv** and the striatum.

N. septofornicatus (Sf)

Location (Figures 1, 2, 60-64): **Sf** appears in the oral parts of the septum on frontal sections as a narrow band in dorsoventral direction; the band is always found laterally besides the descending fibers of the *Fornix longus*. It is embedded in a well-defined fiber mass accumulated parallel to the fornix fiber pattern. **Sf** forms a link with the *Fornix longus* caudally as well

in the *Pars fimbrialis septi*. In the latter case, **Sf** is located in the angle formed by *Fornix longus* and *Fornix inferior* (see Figure 63). The entire length of **Sf** is laterally, and in part also dorsally, delimited by **Sv**.

The caudal part of **Sf**, identically with the *N. septoventricularis*, constitutes part of the *N. septalis fimbrialis* according to Loo. The question it raised whether the various fiber compounds originate from two components (**Sv** and **Sf**) which form Loo's *N. septalis lateralis* as well as *N. fimbrialis*. Loo definitely stated that no structural differences exist between *N. septalis lateralis* (oral) and *N. fimbrialis* (caudal).

In **Sf**, the following is determinable: a ventral sub-nucleus (**Sf.v**), which can be additionally divided into a ventrooral (**Sf.v.o**) and a ventrocaudal (**Sf.v.c**), nucleus; in man, an apparently quite rudimentary dorsal sub-nucleus (**Sf.d**) is also determinable. Figure 1 merely shows **Sv.v.o** with a dorsally located small island of **Sf.v.o**.

a) **N. septofornicatus ventralis (Sf.v.)**

Location (Figures 1, 2, 60-62).

C (Fig. 2): Neurons: smaller; nucleus and cell body considerably darker than in **Sv**; plump, spindle-type shape. The rapidly rejuvenating apical process is clearly evident as a basal extension; the base is frequently rounded. The longitudinal axis of neurons, as in **Sv**, is mainly dorsomedial. Ventrally, the neurons form several dense accumulations (Figure 1); dorsally, they are increasingly scattered among the infiltrating fibers. The difference between the oral and caudal component is minor, but well-defined. The neurons of the oral sector are larger, plumper and show stronger staining (Figure 4); the neurons of the caudal sector (Figure 5) are slightly smaller, slimmer and show lighter staining; otherwise, their form and distribution is

identical. The oral part in man is characterized by larger neurons and by more pronounced formation of (cell) accumulations, as compared with the caudal part (see Figure 1).

M (Figure 2): **Sf.v.** always shows pronounced lighter staining where accumulations of neurons are located in the aforementioned fiber mass. Its structure is not reliably distinguishable from the structure of the infiltrating fibers. In the case of **Sv**, the characteristic, rough single fibers are missing. No discrimination can be made between the oral and caudal subsection.

b) N. septofornicatus dorsalis (Sf.d.)

This sub-nucleus represents a clearly delimited, well-developed area in the Cercopithecus and also in the chimpanzee; the corresponding neurons in man, sporadically scattered between the fibers, must be separately considered, as a specific sub-nucleus of the basic ventral part.

Location (Figures 61-64).

C (Figure 6): Neurons: smaller and mostly slimmer than those of **Sf.v.o.**, but of the same type. They are always definitely smaller and stain darker than the neurons of **Sv**. Very rich in glia.

M (Figure 2): Occurs in the fiber pattern as an orally loose fiber field which becomes increasingly dense in caudal direction. Present next to fine and also roughly calibrated fibers in small quantities. Always sharply divided from Fornix longus, due to significantly reduced density.

As in case of *N. septoventricularis*, no structural correlation with the striatum is determinable here either.

Rose (1927) represents this nucleus in the ape, in its dorsal form, parallel with the fornix (his Table 46, Figure 3), as layer a. On the other hand, he represents the layer of the *Fornix longus* as I, describing the part near the ventricle (our **Sv**) as the "striatal" part of the septum. When doing so, he starts from the idea that the septum represents part of his striatal (semicortical) cortex. Based on structural findings and on comparative-anatomical data, his opinion must be entirely rejected (see also p. 27 of German text, and following pages).

N. interformicatus septi (S.if)⁴ and Commissura subformicalis

Location (Figures 62-64): **S.if.** closely adjoins **Sf.v.** (**Sf.v.c.**). It is thereby located laterally from *Fornix inferior*, between the latter and the ventricle wall. On sections located more caudally, it is found in some groups, distributed between the fornix bundles; even more caudally located, it is found, once more in groups, ventrocaudally positioned from the *Fornix inferior*, parallelly with the fibers of the subformic commissure.

C (Figures 7, 8): Neurons: average-small, slim fusiform cells, with long, fine processes. Where the cells are pressed in among the fibers, the nucleus is relatively large, spherical to plump-oval, and mostly darker than the plasma. The cell plasma is visible at the apex and base only; fine-grained Nissl-substance is evident. Between fibers, the shape of the nucleus becomes

⁴ This nucleus is unrelated to the nucleus defined by Greving as *N.interformicatus*, located in the hypothalamus. On the other hand, it corresponds possibly to *N. septalis trianguldris*, found by Cajal in *Didelphys virginiana* (Loo, 1931).

elongated as well. The patterns of the neurons are - according the fornix and commissure fibers - highly irregular. Large cells are very rarely present; they are similar to the striatum cells (see below, p. 16 of original text).

M (Figure 10, left top): Very medulla-deficient. Fine single fibers, scarce Gf (ground fiber meshwork). In oral sections, cannot be distinguished from the ventrally situated *N. parvocellularis septi*.

As mentioned earlier, the extreme caudal processes of **S.if.** run parallel in caudoventral direction with the fiber structure of *Fornix inferior*; the fibers appear in loose but clearly determinable bundles. These fibers form a well-defined commissure (Figures 9, 10) between the fornix and several compact fiber bundles, progressing caudoventrally from the fornix (more evident in Figure 10 than in Figure 11). Said commissure occupies an immediately oral position relatively to the subfornical organ of the IIIrd ventricle (Pines, Dannheimer). O. Vogt (1895) was first to describe the aforementioned commissure in the mouse and in man as *Psalterium orale ventrale*. He named another, more caudally and dorsally located commissure.

According to Vogt both allegedly consist of the intersecting fibers of the extraventricular alveus⁵. It is quite possible that fimbria fibers intersect in the shown commissure. Loose fibers of finer caliber, jointly with the aforementioned fiber bundles, can be observed up to the intersection at issue, in the cleft between the two fornix sides of the caudodorsally located intersection, Vogt's *Psalterium orale dorsale*. The quantity of the fibers intersecting here indicates the probability that other fibers are additionally present as well. Standard anatomical preparations suggest that a large part of the fibers terminates in the dorso-oral gray or that it originates from there (see Figure 10). In that case, the commissure of the septum gray would be at

⁵ Shimazono (1912) also described said commissura in man (see Figure 2, 52, 5b). He interpreted it as a sector of the psalterium which remained in the oral part.

issue. I propose the name *Commissura subfornicalis* for this intersection; the definition does not presuppose anything regarding the origin of the fibers. It might represent a remnant of the oral portion of the *Comm. hippocampi* (Herrick, 1910; Johnson, 1915; Loo, 1931).

N. parvocellularis septi (S.pc.)

Location (Figures 1, 2, 60-62): **S.pc.** is ventrally located relatively to the *N. septofornicatus* and *N. interfornicatus*, always on the medial side of the lower ventricle angle. It is located caudally from the oral part of the *N. septoventricularis*; however, at variance from *N. interfornicatus septi*, it is always positioned orally in front of the descending fornix column. It adjoins the prothalamus (preoptic) areas ventrally and adjoins the striatum ventro-laterally, separated by a cell-deficient zone.

C (Figure 11): The dimensions of the cells are very small. The distribution of the cells shows uniform density. Three cell types can be discriminated:

- average-small Spz which predominate; their nucleus is globular, with well-defined narrow protoplasm lining and numerous, rather long processes (↑1 IN Fig. 11). The nuclei of these cells show a remarkably high incidence of aggregates.
- Neurons of half-to-two-third size, as compared to the above, are less frequently found; they are slimmer, spindly, very dark and also show long processes (↑2). Both cell types are characterized by well-defined cytoplasm delimitation as seen from the exterior; the long processes represent a feature which differs from the characteristics of the small striatum cells.
- Large, tigroid-rich striatum cells are sporadically present; these, as well as the still rare cells in S.if are similar to the large striatum cells (↑3).

M (Figure 2): Extremely medulla-deficient. Fine, short single fibers. Cannot be separated in the fiber pattern from the dorsally located oral **S.if.** part.

This gray, as well as the previously discussed *S.if.*, definitely differs from the striatum tissue, despite the incidence of large neurons (see also p. 16 of original text). If any relationship exists at all, such relationship would rather be structural between **S.pc.** and an orodorsally located sector of the prothalamus; topographically, **S.pc.** penetrates into the area of the latter (Figure 61).

Discussion of the Results

1. In man, the septum gray as such was described as a cell mass, which is developed principally in the oral part of the septum where it is mainly located laterally from the *Fornix longus* and orolaterally, from the *Columnae fornicis*. Parallel with these two fiber bundles, it extends far, in caudal direction, and terminates approximately (where both *Fornix columns* separate once more), at the base of the *Corpus callosum*, subsequently progressing in laterocaudal direction.

Four units are delimited in this area:

- the laterodorsal *N. septoventricularis* (**Sv**),
- the medially positioned *N. septofornicatus* (**Sf**),
- the *N. parvocellularis septi* (**S.pc.**), ventrally and orally located from the fornix inferior and
- the *N. interfornicatus septi* (**S.if.**), located more caudally from the latter.

Despite the substantial structural differences between individual areas, the shared characteristics., especially those of cell structure, are nevertheless so significant that this area can be defined as a higher-ranking unit from a structural standpoint. It can

be unequivocally homologized as a whole as well as regarding its single components in the mammalian series, as far down as the Didelphyidae. The investigations of Johnston and Crosby (reptiles) and Herrick (amphibians) permit the homologization of this area, at least as a whole, for the lower vertebrate classes as well (see p. 5 of German text). Septum gray was differentiated at an early date, at least in rodents (rabbits); it is valid for primates and man as well, i.e., regarding its differentiation, septum gray, as compared with the striatum, belongs to the phylogenetically ancient areas of the forebrain.

The large-cell gray, located medially from this area in the septum, is to be classified as belonging to the basal nucleus complex, due to its cellular structure; accordingly, it does not form a true septum nucleus.

A third zone, found in most vertebrates (including the lower primates) is located in the septum. Structurally, it is part of the striatum (*N. accumbens*). In man (as a result of adhesion of lower ventricle angle surfaces), it is no longer positioned on the medial (septum) side and therefore does not belong to the septum gray topographically either.

2. A closer structural correlation between the septum gray or its components with the striatum does not exist. The well-defined structural difference between nerve cells of both areas separates the two areas in principle from each other, despite small cell dimensions and medullary deficiency which characterize the septum gray as well as the striatum. On the other hand, an unmistakable structural relationship is evident, especially between the ventral nuclei (*N. interfornicatus septi* and *N. parvocellularis*) and the oral areas of the prothalamus (preoptic area of the Americans⁶ which areas (in a wider sense) should

⁶ It is of interest in this context that according to the stimulation test results obtained mainly by Hess and the Ranson's School, the ventral part of the septum gray seems to participate in functions of a vegetative type, similar to those of the prothalamis area (see Boon, 1938).

be regarded as belonging to the hypothalamus. As far as any conclusions can be reached on the position of an area relative to other centers according to standard anatomical findings, the localization, structure and fiber compounds (see below) visible in standard preparations speak in favor of the aforementioned relationships with the hypothalamus on the one hand; on the other hand, these findings speak in favor of close correlations with secondary and higher olfactory centers, principally as a result of comparative anatomical investigations.

3. The symmetrical position of the septum gray as related to fibers does not result from standard anatomical studies focused on the medullary sheath in man. It is possible that the fibers, penetrating into the oral part of the *N. septoventricularis* from a ventral direction, terminate or originate there, respectively.

The fibers at issue here are those of the diagonal band (Broca), which probably correspond to those of the commissural bundle. According to Cajal and E. Smith (1904), some of these fibers terminate in or originate from the septum. It is not determinable whether, and how far, the fibers of the *Fornix longus* terminate in the septum gray, as the two aforementioned authors contend, especially with reference to the lateral part. Fibers which, in lower vertebrates, belong to the large medial forebrain bundle (linkage of the septum with the midbrain) cannot be isolated with standard anatomical methods from the fibers of the diagonal band and from the residual fiber systems. At the intersection specified as commissura surforminalis (*Psalterium orale ventrale*, O. Vogt) fibers from the bilateral septum gray are presumably present.

II. The Striatum

Much has been written by those active in the normal-comparative, and pathological-anatomical field about the fundamental structural difference between the caudate nucleus and putamen, specifically known as striatum and on the globus pallidus, forming part of the corpus striatum. They need therefore not be discussed here. The same applies, especially in man, to the topography of these brain components. The following statements deal with the first-mentioned component, the striatum, as interpreted by C. and O. Vogt, Spatz and others.

In general, the cyto- and myelo-structure of the various striatum components are considered to be of a similar type. Few references are found in literature on cell structure differences between these components. C. Vogt (1911), Bielchowsky (1919), and C. and O. Vogt (1920) refer occasionally to differences between the small striatum cells: to those in the N. caudatus (larger), and in the putamen (smaller). The analysis of Gurewitsch (1930) is much more thorough; he conducted comparative anatomical studies in mammals as well. This author certainly detected true and typical structural differences. However, the structural data, the illustrations and diagrams are inadequate; they are hardly usable for a classification. In the first place, the contention that the striatum is a cortex-like formation, while equating cell features present in the caudatus and putamen with the cortex layers, must be defined as entirely erroneous. Wherever the analytical findings of Gurwitsch unquestionably coincide with my own findings, the fact will be indicated in the text.

A larger part is played, mainly in comparative-anatomical literature, by the striatum zone generally known as "the head of the nucleus caudatus," i.e., the zone protruding in the *Substantia perforata anterior* over the olfactory tubercle (*Tuberculum*

olfactorium). It corresponds to the *N. accumbens*, (Ziehen, 1908, Marsupials), to the *N. accumbens septi* of Kappers (1908, 1921), to the *N. parolfactorius lateralis* and to the "bed of the stria terminalis" of Johnston (1913, 1923), as well as to the *N. accumbens* of Kodama (Human, 1926). In general, all these zones should not be delimited according to exact structural viewpoints; instead, they should be delimited according to more or less unequivocally determined topographical viewpoints.

The striatum is cytoarchitectonically characterized by:

1. its allomorphic structure as interpreted by Kohnstamm: it contains numerous small and medium-sized striatum cells;
2. by the specific features of its cell structure.
 - a) small striatum cells: polygonal to plump-oval, relatively large, rounded nucleus with lobular nucleolus and scattered chromatin fragments. Narrow, slightly chromophilic plasma border; its external limit is difficult to determine. Fine processes, evident with stronger magnification only.
 - b) large striatum cells: polygonal, or showing a slim, pyramidal shape. Globular-oval, darkly stained, mostly extentrically positioned nucleus with large nucleolus and often with well-defined nucleolus vacuole; clear nuclear fluid. Lipophylic. Nissl substance: rough plates; frequently stichochromic pattern of the Nissl substance, with tendency to the formation of peripheral lumps. Vigorous, tigroid-deficient processes, often with well-defined branching cone at bifurcation points. Strong satellite formation. For additional histological details, see Bielschowsky (1919).
3. Characterized by a basic substance which stains stronger with the Nissl method than it does in most other gray areas.

The incidence of medium-sized neurons among numerous small cells was emphasized also when describing small-cell septum nuclei (**S.if.** and **S.pc.**). However, the structural characteristics of all these areas differ to such an extent from the typical striatum structure that they cannot be defined as striatal on the basis of these characteristics (see also p. 13 of original text).

Myeloarchitectonic characteristics:

1. Loose network of fine Gf ("Grundfaern", ground fibers) and of mostly fine single fibers. Additionally, lots numerous, slightly rougher single fibers.
2. Comparatively few penetrating single fibers and fiber bundles.
3. Characteristic vigorous and definitely separate fiber bundles, found mostly in the central sections; they serve as links between the striatum and other centers.

The two first-mentioned factors account for the brightness in the fiber pattern, characteristic for the striatum.

We start from Figure 12 when analysing the striatum.

Figure 12. Section through the oral striatum. The frontal commissura and the external link of the pallidum are barely visible in the section. Dorsomedial of the caudate nucleus (**Cd**), ventrolateral of the putamen (**Pt**). Ventromedially, an area is seen which corresponds to the N. accumbens of Ziehen (Marsupials) and Kodama (man). Kappers and Theunissen (1908) confirmed that this area belongs to the striatum.

The investigations of Ziehen and of the two last-mentioned authors were mainly focused on the fiber pattern. However, it will be shown below that, more so than in case of myeloarchitecture, cytoarchitecture necessitates the delimitation of this complex from the rest of the striatum. Moreover, an exact anatomic study reveals that according to the findings of Ziehen and Kodama, the N. accumbens unites two very different formations: the medial formation, the Callejan islands, a component surrounding the area connected with the aforementioned formation, which is probably correlated with olfactory centers, mainly of the secondary type. The second formation is a lateral component, which is substantially more closely related to the rest of the striatum, structurally as well as functionally. In accordance with Calleja (1893), I define the first component as *Insulae olfactoriae striatales* (**I.o.s.**) (see below, p. 25 of German text). For the second component, more closely related to the caudate nucleus and to the putamen, I propose the name *N. fundamentalis striati*, or briefly: *Fundus striati* (**Fu**). Ventrally, these two areas which jointly form the *N. accumbens* of Ziehen, are connected with the brain surface. (See p. 27 of German text for information on the human cortex of the olfactory tubercle). Two larger islands of a nucleus appear laterally from our ventricle angle, below the caudate nucleus and embedded in the *Fundus striati*, which gradually disappears here. This nucleus differs from the structural pattern of the entire striatum, more so than the *Insulae olfactoriae striatales* (see p. 30 of German text). Such a nucleus is found in all primates; to the best of my knowledge, it has not as yet been described. I propose the definition *N. subcaudatus* (**sc**). While certain areas, as compared with the entire striatum, are specific from several viewpoints, they will nevertheless be described in connection with the *Fundus striati* to which they are topographically as well as structurally more closely related to this striatum component than to other components.

a) Fundus striati (Fu)

Location (Figures 12, 54-63): The *Fundus striati* is developed in the oral part of the striatum only (see the diagrams), where it occupies the ventromedial area, seemingly forming a connecting bridge between the caudate nucleus and putamen, ventromedially from the internal capsule, from the anterior commissure and pallidum. Dorsally, the *Fundus striati* reaches as far as the lower ventricle angle, separated from the ventricle wall by a wide matrix layer. Medially from the *fundus striati*, the oral origin of the prothalamus and septum gray is dorsally located; it is located ventrally of the fiber field of the diagonal band. Ventromedially, the *Fundus striati* adjoins the aforementioned *Insulae olf. striati*; ventrally, it adjoins the lateral of the two cortex fields of the *Tuberculum olfactorium (Tb.I)*. Ventrolaterally, the *Fundus striati* connects with parts of the *N. olfactorius anterior* (very rudimentary in man) and with the *ventral Claustrum insulare (Cl.i.v.)*. It is separated from them by a thin fiber lamella only. In sectors more orally located than those shown by section 12, the *Fundus striati* is ventrally surrounded in all locations by the medulla of the *G. olfactorius medialis* and by the basal frontal brain convolutions. Specific sectors delimited in the Figure and their topographical status will be discussed when describing these sectors.

Shared structural characteristics of the individual *Fundus striati* sectors:

a) Cytoarchitecture as compared with **Cd** and **Pt**:

1. The small striatum cells are significantly thicker; very minor content of large elements.
2. Dimensional decrease of the small and large neurons. This decrease is quite pronounced in most sub-nuclei; on the other hand, it is quite minor in the *Fundus putaminis* near the putamen (see below).

3. Much more irregular cell distribution. Formation of cell accumulations and cell strings.

4. Stronger staining of the basic substance.

b) Myeloarchitecture:

1. Gf (ground fibers) and single fibers contain much less medulla; they are to be defined as natural fibers.

2. Few splintering fiber bundles. The latter are generally much thinner than in **Pt**. On the other hand, the ventrolateral part contains numerous, definitely **Fu**-infiltrating bundles (partially aberrant fiber bundles of the internal capsule).

Therefore the *Fundus striati* seems to be generally medulla-deficient; in the fiber survey illustration, it differs more conspicuously from **Cd** and **Pt** than in the cell pattern illustration (Figure 12).

Four dissimilar structural areas can be discriminated in the *Fundus striati*:

- the *Fundus subventricularis medialis* (**Fu.sv.m.**), nearest to the Ins. olf. striat. and to the ventricle angle; the more laterally and ventrally positioned
- the *Fundus subventricularis lateralis* (**Fu.sv.l.**) which encases the **Fu.sv.m.** everywhere, except medially;
- the *Fundus caudati* (**Fu.cd.**) which approximates the caudate nucleus topographically and structurally, and
- the *Fundus putaminis* (**Fu.pt.**) which is likewise closely related to the putamen.

Figure 13 shows the cell pattern over the fundus part which is located near the ventricle. A fraction of the septum gray is visible to the right on top (**Sv**). A space very poor in neurons is ventrolaterally adjoined here by the *Insulae olfactoriae striatales*, extending in dorsal direction and connected with the small-cell *Fundus subventricularis medialis*. Between **Fu.sv.m.** and the

laterally adjoining, also small-cell *Fundus subventricularis lateralis*, we find a broad band, of subependymal tissue, the residue of the adhesion located in the lowest ventricle wall sections. The caudal rudiment of the definitely large-cell *Fundus caudati* follows laterally from **Fu.sv.l.**, as well as the ventromedial part of the caudate nucleus. The bundles of the internal capsule infiltrate to the left on top between the fundus sectors and separate these into cell strings.

The boundaries between the individual striatum nuclei in this figure and in the following figures are indicated by lines. This does not mean that the delimitations are of "linear" precision in each case, or, respectively, that we can make determinations with such a precision, as demonstrated in other cortical and subcortical fields. On the one hand, more or less strong "limitrophic adaptations" (C. and O. Vogt, 1919) exist between specific striatum nuclei; on the other hand, cell type differences in the striatum are minor. It is therefore not possible to determine reliably to which subnucleus they belong (see also the description of individual boundary in the illustrations, shown as examples).

My description of individual fundus nuclei begins with

The Fundus subventricularis medialis (Fu.sv.m.: the N. caudatus ventralis, Cv, of Gurewitsch).

Location (Figures 12, 13, 57-61): The **Fu.sv.m.** is always found located ventrally from the lower ventricle angle, reaching slightly up, in mediodorsal direction.

C (Figures 13, 14, 15): Characterized by very small, dense cells. Small striatum cells: rounded to plump-oval, partially spindly with very dark, globular nucleus. A cell-deficient zone containing still smaller cells always develops in the direction of the subependymal tissue. The same occurs in **Fu.sv.l.**; see Figure 13. Large cells: scarce, but relatively large.

M (Figure 12): Extremely medulla-deficient. Very few, fine and short single fibers, somewhat longer than in **S.pc.**

Fundus subventricularis lateralis (Fu.sv.l., sector of Cl according to Gurewitsch.

Location (Figures 12, 13, 55-62): Except medially, **Fu.sv.l.** encloses **Fu.sv.m.** on all sides. On frontal sections: laterally and ventrally from **Fu.sv.m.**

C (Figures 13, 14-16): Figure 14 refers to a sector in the vicinity of the ventricle. Small cells, definitely more loosely positioned but generally not larger than those in **Fu. sv.m.** Large neurons: similar to the latter. The aforementioned process of the subependymal glia tissue is located between the two sub-nuclei; slim, average-sized and dark fusiform cells are scattered in said tissue. I was unable so far to classify this group which is variously developed in various brains (for example: it is significantly larger in A 61). In *Lemur catta*, the group is considerably larger and radiates into the fundus from the ventromedial direction.

Figure 16 reproduces a section of the more ventrally located area.

Uniform parallel cellular pattern (string formation). All neurons are larger than in Fig. 14. Since a quite gradual approximation is found between the two parts and since some identical cells are found dorsally as well, a separation could presumably be dispensed with.

Figure 15 shows the boundary between **Fu.sv.m.** and **Fu.sv.l.**, in the same section as shown by Figure 16, in ventral direction. Lower magnification was applied in Figure 15. The boundary is adequately well-defined. The order of magnitude of the structural difference between the two nuclei is clearly expressed.

A sharply delimited zone is usually found in the more caudal planes than those in Fig. 13, in the vicinity of the internal capsule. In this zone, the neurons are slightly larger and less densely distributed (Fig. 62, Fu.sv.l). The dimensions of the big striatum cells are also somewhat larger than in the remainder of the zone.

M (Fig. 12, 20): High-grade medullary deficiency (markarm) as in case of **Fu.sv.m.** Slightly increased density of the basic fiber network and more numerous, somewhat rougher single fibers than in **Fu.sv.m.** The major part of the single fibers progress in sagittal direction. Definitely less dark than **Fu.pt** (see below). In **Fu.sv.l.**, the single fibers are slightly longer and rougher than in the rest of the **Fu.sv.l.** Sporadic incidence of accumulated, very rough single fibers and Fb are presumably not eigen-fibers ("Eigenfasern").

Fundus caudati (**Fu.cd**, part of C1 according to Gurewitsch).

Location (Figs. 12, 13, 54-60): Between the caudate nucleus and the rest of the *Fundus striati*. Developed principally in the oral part (see Fig. 54-58).

C. (Figs. 13, 17): **Fu.cd** is characterized by significantly less, but definitely larger cells, as compared with **Fu.sv.** Small cells: more plump and more similar to the polygonal form of the cells of the caudate nucleus. Large neurons: also larger, more numerous than in **Fu.sv.** **Fu.cd**, as related to the caudate nucleus, shows an especially wide limitrophic zone; therefore, delimitation in the oral part encounters considerable difficulties.

M (Fig. 12): Richer in fibers than **Fu.sv.l**. No ground fiber-network is visible. Fine single fibers form a loose but well-defined network in the central part (in the vicinity of the internal capsula) rougher single fibers are scattered as well. Here, numerous, mostly crosscut fiber bindles with fine and less rough fibers are also present. The more fiber-deficient, ventral process of the tangential band characteristic for the caudate nucleus is located at the ventricle rim (C. and O. Vogt, 1920, see also p. 37 of original text).

The *Fundus caudati* definitely holds an intermediate position regarding cellular and fiber patterns, between the *Fundus subventricularis lateralis* and the caudate nucleus.

Fundus putaminis (**Fu.pt**, Pv according to Gurewitsch).

Location (Figs. 12, 54-63): **Fu.pt** is located ventrolaterally from the *Fundus subventricularis lateralis*, between the latter and the putamen. At variance from the *Fundus caudati*, it is more developed in the caudal fundus area.

C (Figs. 18, 19): Small neurons: as compared with **Fu.sv.l**: wider, looser and more regular distribution, significantly less cell string formation. Only slightly smaller than in **Fu.cd** (Fig. 17). Large neurons: Incidence somewhat higher than in **Fu.sv.l**. Figure 19, with 100 x magnification, shows the boundary of **Fu.sv.l** and **Fu.pt**, in the section also shown by Fig. 18.

M (Fig. 20): Significantly richer in fibers than **Fu.sv.l**. Well-defined network of fine single fibers, as in **Fu.cd**, but more dense than in the latter. Numerous rough single fibers; as in case of the numerous fiber bundles, no reliable distinction can be made

between native and foreign fibers. Some of the fiber bundles which penetrate the **Fu.pt** dorsomedially belong to the medial olfactory tract, infiltrating the anterior commissure.

The *Fundus putaminis* represents an intermediate structural step between the *Fundus subventricularis* and the putamen.

SUPPLEMENT

1. Insulae olfactoriae striatales (I.o.s.)

The area for which the above definition is used includes more than the total of the cell groups described by Calleja (1892) as "*islotos olfactivos*". Besides Calleja's small-cell islands, the area also includes the medial, large-cell residual component of the *N. accumbens* of Ziehen, et al., which is rather rudimentary in Man (see p. 17 of German text). In the macrosomatics (in *Lemur catta* as well), this nucleus, forming a more or less complete unit, is always divided in Man into several cell islands of varied size. They are closely united with the small-cell parts forming a thoroughly homogeneous unit in Man. In macrosomatic mammals (lemur, dog, rabbit, mouse) the fusion is less complete. But here, the large-cell component is also largely penetrated by small-cell islands. The formation of numerous individual zones is determinable here as well, especially in the higher primates. From the viewpoint of differentiation, these zones obviously represent intermediate steps between both extremes and presumably unite them in this respect as well (see Fig. 22).

This curious formation merely parallels cell islands in Man localized at the ventricle rim of the amygdaloid nucleus (*Mandelkern*). The formation (**A.p.v.** gl.) was detected by Brockhaus (1938); but its presence had already been confirmed by Meynert (1872). However, Calleja was probably first to demonstrate the close correlation between the latter and the olfactory centers: his findings make a fiber-link with the olfactory bulb seem highly probable.

If this is so, especially in Man and in the higher primates, the *Ins.olf.striat.* form a structural unit, despite their structural dissimilarities. On the other hand, comparative anatomic findings in macroamatics nevertheless show that the two components are of dissimilar origin: the small-cell part of the true Calleja islands develops initially mixed with striatal cell groups, in the cortex of the olfactory tubercle (see below, p. 29 of German text) and can be verified in the mouse, in an oral direction, in the most superficial ventral layers of the *Lobus olfactorius*, extending approximately up to the median elevation of the *N. olfactorius anterior* (Crosby and Humphrey, 1938). But in the strict sense of the work, they do not belong to the striatum.

The large-cell part (Figs. 22. 2), on the other hand, constitutes the true striatum component and terminates in oral direction in the macroamatics as well, approximately at the elevation of the fundus end, or respectively, jointly with the cell band of the olfactory tubercle. It is always definitely separated from the *N.olf.ant.*

Location (Figs. 12, 59-62): In the adult human brain, the localization of the *Ins. olf.striat.* corresponds obviously with the localization of the hemispheric component of the embryonal olfactory ventricle. This becomes clearly evident when comparing Fig. 21, obtained from Hochstetter's findings (1919), with Figures 12, 59-61. Hochstetter describes the laterally

caudal direction of the olfactory ventricle's hemispheric component, from the inferior recess of the lateral ventricle, proceeding up to the olfactory tubercle. This direction is also followed by the *Ins.olf. striat.* (see Spiegel, 1919). The *Ins.olf. striat.* are thereby located medially, ventromedially, ventrally and ventrolaterally from the *Fundus striati*, forming an arc which is ventromedially convex; starting from the lower ventricle angle, this arc extends laterally in lateroventral and caudal direction up to the olfactory tubercle, within which it proceeds once more for some distance in oral direction.

Lateroventrally from the olfactory tubercle, groups of islands are always present in the lowest sector of the external capsula, between the claustrum and putamen.

C (Figs. 13. 22): More or less clearly defined islands are found in the fundus area, in which the neurons show identical differentiation stages within individual islands, while considerable differences exist in this respect between the various islands. Figure 22 shows five such dissimilar differentiation stages (1-5). In the island located to the right top, glial elements - except for a few large striatum cells - cannot be differentiated from nervous elements. These correspond to the periventricular olfactory bulb (Brunner's internal granular layer, 1923) according to the size, disposition and density of the cells, they also correspond to the small-cell islands of the aforementioned amygdaloid cell zone **A.p.v.** gl. Location 2 in the illustration is part of the **J.o.s.** component, which forms a closed nucleus in the macrosomatics.

M (Fig. 12): Not uniform in the fiber pattern either, in accordance with the dissimilar differentiation grade of the neurons. Besides highly medulla-deficient islands which are conspicuously light, islands are evident in which a fine- and long-fiber network is definitely evident. The fundamental studies of Callaja demonstrated that the aforementioned deficiency is mainly a lack of medullary fibers and not of fibers without medulla.

It can be assumed that the *Ins. olf. striat.* are correlated with the olfactory function.

2. The cortex of the olfactory tubercle

Rose (1927) listed the olfactory tubercle of mammals, including Man, with the *Cortex semiparietinus (Semicortex)*. This is not correct in this form, for the following reason: In microsmatic apes and especially in Man, the cortex layer, homologue with the olfactory tubercle cortex of the macrosomatics, is not present at all, or only as a minor rudimentary remnant; these remnants are no longer functional. The semi-cortical character of these rudimentary remnants will be discussed below. In the major part of the olfactory tubercle, the striatum tissue (*Fundus subventricularis lateralis*) is located free on the brain surface. Its maximally superficial layers show partial and minor modification, which could possibly be defined as to "cortex analogous" (see also Beccari, 1910 and Kryspin-Exner, 1922).

The question remains open how far the aforementioned remnants of the original olfactory tubercle cortex in macrosomatics can be defined as semicortical. In macrosomatics, no link exists along longer stretches between the striatum and the cortex of the olfactory tubercle. Only smaller uvula (extensions) of striatal tissue extend occasionally in ventral direction through the so-called "deep layer of the olfactory tubercle" (basal nuclear component), up to the cell band (studied animals: *Lemur catta*, dog, rabbit and didelphys). In a previous study describing the amygdaloid cortex (1938), the definition *Semicortex* was used with reference to the condition of the mature brain. But this definition is hardly adequate with reference to the link between the striatum and the olfactory tubercle. It is possible, on the other hand, that the ontogenetic striatum and the olfactory tubercle (except for the "deep layer") originate from the same layer (Rose, 1926; Beck, 1940). If so, the olfactory tubercle - in accordance with the ontogenetically supported definition of Rose - is, in fact, semicortical. (See also Herrick., 1927.) According to Rose, the olfactory tubercle of mammals originates from the *N. olfactorius anterior* (medial and ventral part) of

amphibians; this, however, does not apply to the origin of the striatum). If - as Beck assumed (1940) - the major part of the cortex, as well as the major part of the toto-parietal Isocortex (Rose) originate from the striatum layer, matrix and vice versa: if the striatum apparently developed from the matrix of the lateral semicortex proposed by Rose (= the striatal cortex) becomes generally invalid untenable (see also Beck).

On the other hand, If we interpret the semicortex as including those cortex zones which remain connected with subcortical zones in mature condition as well, then the Rose definition of semicortex merely refers to the amygdaloid cortex; In Man, it merely refers to a small medial section of the *A. praepyriiformis dorsalis* (whereby the latter possibly became "secondary semicortical" in primates only, following the reduction of the praepyriiform cortex). Rose includes the *Septum pellucidum* and the *A. diagonalis* among the semicortex areas; but these do not represent cortex areas at all. The olfactory tubercle of the macrosomatics, however, and the major part of the praepyriiform cortex can be described as semicortical on the basis of the ontogenetic definition only.

Figures 23 and 24 show the human remnants of the cell band of both fields of the olfactory tubercle, well-developed in almost all macrosomatics of the mammalian series; they are shown in their maximal extension. The homology of these rudimentary remnants is unequivocally determinable by means of comparisons with the corresponding brain areas in the studied representatives of the primate series.

Both "fields" represent not quite continuous, irregular, wide bands of densely located small grains which are discernible as nerve cells with strong magnification only. They are slightly larger than the glia cells and than the grains of the Calleja islands. Larger forms with small processes occur sporadically among them.

Figure 23 shows the rest of the lateral field in Brain A 45, representing a development which I observed in no other human brain. A near-continuous band of neurons is present here; they are definitely smaller than those in the striatum; the band is separated from the striatum by a much more cell-deficient space. In almost all other brains, only fractions of this cell band are present, similar to those shown by Fig. 24. The boundary between C and the wider *Lamina zonalis* is also quite evident.

In the rest of the medial field (Fig. 24), the grains are generally somewhat larger and their distribution is mostly looser. The medial field, as well as the field shown by Fig. 23, are separated from the striatum by a narrow space, containing almost no neurons at all.

The striatum extending to the brain surface is slightly loosened only in lateral direction, within the fundus area (**Fu.sv.I**), as compared with the deeper parts. Medially within the zone of the *Insulae olfactoriae striatales*, small celled Calleja islands extend laterally near the surface, while the large-celled components (see Fig. 24, right) mostly display a cortex-like structure (a more uniform, more radial disposition of the smaller elements; more pronounced delimitation against the wider, fiberrich external layer, comparable to a *Lamina zonalis*).

3. N. subcaudatus (sc).

This nucleus is located in immediate caudal direction from the part of the fundus in the vicinity of the ventricle; it is located ventro-medially from the caudate nucleus. Its position, as related to the fundus and as related to the entire striatum, is specific, due to its unusual structure. According to its strongly staining basic substance, the dimensions of its neurons and according to loose cell disposition, it seems to be related to the medial caudate nucleus. However, the subcaudatus in Man as well as in the primates lacks one of the essential striatum characteristics, i.e., large striatum cells are missing. Such cells, whenever sporadically present, are always located so close to the border zone (see below) that they must be defined as belonging to the fundus nuclei proper.

Location (Figs. 12, 61, 62): The *N. subcaudatus* is located ventrally from the caudate nucleus, laterally and caudally from the *Fundus subventricularis lateralis* and in the immediate oral vicinity of the *Stria terminalis* fiber system, which extends into the Prothalamus cell area; the *N. subcaudatus* is located orally from the gray surrounding the last-mentioned area. The *N. subcaudatus*, especially in Man, is inclined to form larger and smaller islands, which are more or less deeply embedded in the fundus subventricularis lateralis.

C (Fig. 25): Isomorphic. The neurons are larger than the small elements in all true striatum parts; some of the neurons are bipolar and show protoplasm-rich processes with comparatively extensive staining; the small islands, in particular, as compared with the small striatum cells, contain large quantities of the tigroid substance. Extremely glia-deficient. The basic substance is strongly stained. An extremely cell-deficient, wide zone is always found at the border which surrounds the

individual islands almost completely on all sides; it is separated from the rest of the tissue, which is very rich in cells. This zone contains the aforementioned sporadically present large striatum cells (see Fig. 29, top).

M (Fig. 26): **Sc** is extremely medulla-deficient. It is, therefore, visible in the shape of light islands, in definite contrast to the already medulla-deficient environment (Fig. 12). Very loose, fine basic fiber network, infiltrated by long, fine- to average single fibers, which seem to radiate from the fiber zone surrounding the **sc**. Standard Kultschitzky-preparations definitely seem to indicate that at least part of the fibers originates from the *Stria terminalis*.

Despite some similarities with the structure of the medial caudate component, this nucleus nevertheless shows structural characteristics reminding us of Malone's tuber-nuclei, especially of the nucleus at the far lateral side. These characteristics consist mainly in the form and disposition of the neurons, as well as in the fact that the neurons are separated from their environment by a characteristic, nearly cell-free border zone. The immediately orolateral position of the prothalamus processes, which are located in maximally oral and dorsal direction, as well as the vicinity and the possible link with the *Stria terminalis*, suggest a closer correlation with the hypothalamus.

b) Nucleus caudatus/ caudate nucleus (Cd)

Due to the separation of the fundus as an independent striatum component, the determination of the caudate nucleus in the ventral gray masses (which had earlier been more or less accurately classified as belonging to "the head of the caudate nucleus") was substantially facilitated. In the first place, this made it possible to compare a zone with specific structure, defined as caudate nucleus, with other zones of the striatum.

Regarding the delimitation of the caudate nucleus, principally in the direction of the basal surface, see the diagrams, **Figures 53-65**. Accordingly, the caudate nucleus reaches the ventral plane of the striatum in quite oral direction only. Said ventral plane includes the fundus and the putamen in more caudal direction. The putamen is separated everywhere from the caudate nucleus(except for a small oral stretch) (Fig. 58) by the internal capsule. Bands of gray matter form links with the putamen, especially in the oral sectors. The oral fusion of the *Cauda n. caudati* with the putamen at the apex at the occipital horn of the lateral ventricle is clearly evident in Figures 66-68 and will be specified below. The formation of the dividing line between the caudate nucleus and the delimiting nuclei varies. In the direction of the putamen, the delimitation is generally well-defined and sharp. Figure 27 displays part of a cell bridge between the caudate nucleus and the putamen, emerging from the internal capsule, shown as an example (see Fig. 65). Despite the deformation of the cell shape and position caused by the fiber masses, the sudden structural alteration is quite clearly evident (decrease of the cell count, reduction of the cell size in **Pt**, as compared with **Cd**; see p. 38 of German text, bottom of page). However, it is questionable here as well whether certain cells belong to the caudate nucleus or to the putamen. The situation differs concerning the limit of the *Fundus caudati*, defined as the intermediate area. Due to less significant differences and to a substantially limitrophic adaptation, a delimitation is less difficult here. However, a sudden structural alteration can be mentioned in this case as well.

Common structural characteristics:

Cytoarchitecture: Small neurons: relatively large with well-defined cytoplasm-except for the neurons of the subcaudatus, which hold a specific position; these are the largest of all striatal nuclei. Their disposition is substantially looser and more regular than in the fundus.

Large neurons: sporadically present, but larger than in **Fu** and **Pt**. See Figs. 27 and 33.

Generally rather glia-deficient.

Myeloarchitecture: Richer in medulla than **Fu**. Besides a low-density basic fiber-network, a similar network formed by fine single fibers is present; between them, less well-defined, rougher fibers are found. Less fiber bundles than in **Pt**. As in the latter, the fiber bundles in **Cd** are mainly located in the central, capsula-deficient and, therefore, pallidus-approximated sector. (For information on the fiber lamella located under the ventricle wall in the external caudate layer, see p. 37 of German text below).

In Man, the two structurally different zones in the caudate nucleus are difficult to distinguish. Much more pronounced differences exist in the chimpanzee and *Cercopithecus*. Especially in the latter, the delimitation of the two zones is remarkably sharp. This leads to the conclusion that such a boundary exists in Man as well. Its reliable structural verification is difficult as a result of the proximity of the two zones, which Gurewitsch detected as well. However, the difference - especially in the oral part - is unequivocally determinable also in Man. Accordingly, we distinguish the medial and caudal component, which represents the principal part of the caudate nucleus (*N. caudatus medialis*, **Cd.m**) and another component, the *N. caudatus lateralis*, **Cd.l**), which is mainly orally and dorsoorally oriented (see also [Fig. 53-64](#)).

N. caudatus medialis/Medial caudate nucleus (Cd.m., Cm, Gurewitrch)

Location (Figs. 12, 53-71): **Cd.m** starts at the ventricle wall and extends not quite as far as the oral pole (terminal) of the caudate nucleus; rapidly increasing in size, it is then located ventromedially from the **Cd.l.** and occupies the maximal sector of the principal part and the entire tail of the caudate nucleus.

C (Figs. 28, 30, 31, 38): Small neurons: average density; the neurons show quite regular distribution of polygonal form. Large, round and oval nucleus, well-defined, pale cell body, predominantly with more pronounced processes than in case of most other striatum nuclei.

Large neurons: often pyramidal and slim, large neurons are sporadically present.

Quite orally in the direction of the ventricle wall, **Cd.m** - as does **Cd.l** - shows a narrow, almost neuron-free zone (Fig. 30), followed by another wider zone directed toward the interior, with definitely less and smaller cells than in the principal component. (The frequently darker staining and the more pronounced pattern of the process here is presumably artificially induced.) This zone is a structural characteristic of the caudate nucleus, in particular, of the **Cd.m.**, corresponding to a specific fiber pattern (see below). It has nothing in common with the cortex layer (Gurewitsch).

Figure 31 shows part of the caudate tail sector: the structure is substantially identical with the structure shown by Fig. 18.

M (Figs. 32, 33): A loose network of fine basic fibers is discernible with stronger magnification only; a loose network of medium-fine single fibers is seen. Moreover, the central areas show scattered, rougher single fibers, which are much rarer than in the putamen. The fiber bundles, which are thinner than in the putamen, splinter rapidly, especially in the parts near the ventricle. The tissue contains minor quantities of rough fibers. Few rough fibers are present in areas near the ventricle as well. The aforementioned fiber layer in the vicinity of the ventricle (tangential layer, C. and O. Vogt, 1920) shows a well-

defined double layer: a narrow, fiber-rich external layer corresponding to the cell-free external zone and a substantially wider, but fiber-deficient internal layer. Its fibers gradually disappear in the single fibers network; the last-mentioned layer corresponds to the cell-deficient wider internal zone in the cellular pattern. At the top ventricle angle, the tangential layer is connected with the *Fasc. subcallosus* (Muratoff). According to O. Vogt (1895), this layer possibly contains association-fibers which interconnect the various parts of the caudate nucleus.

The fine single fibers increase significantly in the tail of the caudate nucleus (Fig. 32), while the basic fiber network remains unchanged. Therefore, the fundus is still very light, despite increased fiber content. Fiber bundles are missing. single fibers are very rarely present.

N. caudatus lateralis/lateral caudate nucleus (cd.l., Cd, Gurewitsch).

Location (Figs. 12, 53-64): **Cd.l** is relatively small in Man; its development is principally oral. It occupies the entire oral sector of the caudate nucleus and adjoins the putamen there (Fig. 54), since the internal capsule in the ventral part is atrophied, its separation from the oromedial subnucleus of the putamen encounters difficulties. In sections showing more caudally located areas, the **Cd.l** occupies the lateral corner of the caudate nucleus (Fig. 63) and disappears approximately at the level from where the oral Thalamus originates.

C (Fig. 29): As compared with **cd.m**, the cytoarchitectonic difference in Man - as stated earlier - is minor. **Cd.l.**: Slightly looser, with smaller cells (see Fig. 28). This, however, refers to the small neurons only; the size of the large neurons is

approximately identical with the cell size in **Cd.m.**; cell density is slightly higher than in **Cd.m.** A minor increase of the glia, mainly in the form of Traban cells, is determinable.

M (Fig. 34): The staining is generally darker than in **Cd.m.** (see Fig. 33, same section). This is mainly due to the fact that the fine-fiber, basic. network shows considerable condensation; it is attributable, to a lesser extent, to the increase of the single fibers. In dorsolateral parts near the putamen, clearly outlined, rough single fibers are more frequently found than in **Cd.m.** They appear predominantly in sagittal direction. The fiber bundles - especially in oral direction - are more numerous than in **Cd.m.**; they are also principally located in the central zones.

c) **Putamen (Pt)**

In principle, the statements made regarding the caudate nucleus (see p. 32 and following pages, orig. text) applies to the position of the putamen as well, within the framework of the entire striatum; it also applies to the putamen's delimitation from the *Fundus striati*. Concerning its border with the fundus, see Figs. 54-63. Accordingly, as in the case of the caudatus, the putamen is not involved in the formation of the striatum component located in the *Substantia perforata anterior*. Instead, the putamen definitely terminates dorsolaterally from the latter along a more or less horizontally adjusted borderline. Its delimitation from the *Fundus putaminis* and *subventricularis* (see Fig. 39) is sharper than the delimitation of the caudate nucleus from the *Fundus caudati*; nevertheless, a limitrophic adaptation exists between **Pt** and **Fu.pt**. The borderline with the caudate nucleus is well defined (see Fig. 27). Its localization proportionately to other organs of the brain (globus pallidus, internal and external capsule,

etc.) is so well known that it need not be discussed here. Regarding the location of its individual components and its correlation with the amygdaloid nucleus zone, see Figs. 35 and 36.

Shared structural characteristics:

Cytoarchitecture: Small neurons: Generally of a smaller type than in the caudate nucleus; cell body poorly defined, larger than in the fundus (except for **Fu.pt**). As compared with all **Fu**-neurons, the **Pt** cells show a more differentiated form: it is more polygonal, with a more clearly defined process design. Density varies considerably in the individual subnuclei.

Large neurons: Their incidence is generally higher than in the caudate nucleus; they are, in part, smaller and less slim with less conspicuous stripe pattern of the Nissl substance.

Myeloarchitecture: Generally richer in fiber bundles than in the caudate nucleus and fundus. The single fibers content fluctuates in each zone to such an extent that no uniform structure exists in this respect. Stronger involvement of rough fibers, single fibers as well as fiber bundles. According to O. Vogt, a fiber network along the borderline corresponding to the tangential layer of the N. caudate nucleus in the putamen becomes evident only when the external capsule is destroyed.

I distinguish between five dissimilar subnuclei in the putamen (Figs. 35 and 26): the

- *N. putaminis*, or briefly, the *Putamen mediale* (**Pt.m**),
- *Putamen laterale* (**Pt.l**),
- *Putamen caudale* (**Pt.c.**, Fig. 36) and
- *Putamen ventrale* (**Pt.v**); additionally listed: the
- *Putamen limitans* (**Pt.li**), which - due to its location in the rest of the primates as well - should be defined as the borderline zone relatively to the amygdaloid nucleus.

Figure 36 shows the subdivision of the putamen and of the caudate nucleus on the horizontal section. It is definitely evident that **Pt.m.** occupies by far the largest among the medial and oral sectors in the putamen, while **Pt.l** appears at this level in a much more caudal direction only. The ratio is reversed in the caudate nucleus: **Cd.l.** occupies the oral sector, while **Cd.m.** occupies the larger medial and caudal sector. **Pt.c.** is located entirely in caudal direction within the putamen. As in Fig. 36, the decrease of the fiber bundles in **Pt.l** is evident here as well, as compared with **Pt.m.** (see also below, p. 43 of original text); the situation is less well-defined in **Cd.m.** as compared with **Cd.l.**

Putamen mediale (**Pt.m.**, Pd, Gurewitsch).

Location (Figs. 35, 36, 53-70): **Pt.m.** is, by far, the largest subnucleus of the putamen. It occupies the entire oral part and, in caudal direction, the medial and dorsal sectors as well. It is always located in the vicinity of the Globus pallidus and borders laterally as well as lateroventrally with **Pt.l**; ventrally, it adjoins the oral sector of the fundus, while it adjoins the **Pt.v** in the caudal area.

C (Figs. 37, 43): See also Fig. 38, same section as in Fig. 37.

Small striatum cells: Evidently smaller and with much looser disposition than in **Cd.m.** The minor density does not result from the fibers which eventually infiltrate the nucleus; instead, it is identical with the minor density found in the dorsal and lateral components, which are not infiltrated by fibers. String-like cell patterns are frequently present between the fiber bundles. The dimension and position of the cells is very similar in **Cd.l** (see Fig. 29). Therefore, their delimitation relatively to **Cd.l** in the oral part is much more difficult than relatively to **Cd.m.** In caudal direction, the small neurons show a moderate but constant density increase.

Large neurons: Minor density increase, as compared with **Cd**.

Relatively glia-deficient.

Figure 39 shows the borderline between **Pt.m** and **Fu.sv.l** with minor magnification. The delimitation is well-defined and sufficiently sharp.

The difference in neurons size (shown: small neurons and two large neurons) between the two nuclei corresponds to standard.

M (Fig. 40, 41): Loose network of fine fibers and likewise loose single fibers network. Between the finer fibers, which correspond to the single fibers of the residual striatum nuclei, numerous rough, mostly longer fibers are evident; their quantity is characteristic for **Pt.m**. They are principally located in the vicinity of the Pallidum area. The bulk of fibers in the fiber bundles corresponds to the finer single fibers; the rough fibers, admixed to the latter, are clearly visible. The difference is especially conspicuous in Fig. 41, where the stronger differentiation highlights the contrast between the rough fibers and the rest of the fiber bundles.

Putamen laterale/ lateral putamen (Pt.l)

Location (Figs. 35, 36, 62-70): **Pt.l** begins only in the central parts of the putamen, located at first ventrally; then proceeding upward dorsolaterally in more caudallypositioned sections; it subsequently occupies the entire lateral part of the putamen. It borders on **Fu** ventrally in the oral planes, and it borders on **Pt.v** in the caudal planes. **Pt.c** is caudally located from **Pt.l**.

C(Fig. 42): Small striatum cells: As compared with **Pt.m** (see Fig. 43), these cells show a definitely denser disposition; they are, in part, smaller and slimmer; their longitudinal axis is mostly dorsoventral. In the oroventral areas near **Fu.pt**, the cells are slightly larger than in the main laterodorsal sector. A cell-deficient zone corresponding to the cell-deficient border zone of the caudate nucleus is not determinable on the external surface of **Pt.l**, nor on the external surface of **Pt.m**.

Large neurons: Their shape and dimensions are similar to **Pt.m**. In general, but especially in more caudally located areas, they appear denser than in **Pt.m**.

Much richer in glia than **Pt.m**.

Figure 44a shows part of the borderline between **Pt.m** and **Pt.l** in the cellular pattern. Since the delimitation is mainly based on the density difference of the small neurons, and not on differences between cells, and since a bilateral limitrophic adaptation exists as well, a sharp delimitation is not possible. As a matter of course, it cannot be determined to which subnucleus individual neurons belong. Nevertheless, the structural difference between **Pt.m** and **Pt.l** is clearly evident in Figure 44a (see also Fig. 42 and 43).

Figure 44b shows the same borderline in the fiber pattern (see Fig. 35). The difference between the fiber content in the two nuclei is more conspicuous. The borderline, therefore, becomes more clearly evident and seems sharper than in the cellular pattern.

M (Figs. 45, 35): Richer in fibers than **Pt.m**. This is mainly due to the increased density of the single fibers-network. The density of the basal network can hardly be evaluated because it is difficult to verify among the single fibers. The direction of the single fibers is mainly dorsoventral. Much less fiber bundles are present. Figs. 35 and 36 show that the fiber bundles are no longer present with their thicker sectors, i.e., they cease at the borderline with **Pt.l**. The much thinner remnants of the

fiber bundles rapidly splinter in **Pt.l**. The number of rough fibers is considerably reduced among the fiber bundles and single fibers. The fiber count evidently increases in caudal and dorsal direction (ground fiber-network ?).

Putamen caudale/ caudal putamen (Pt.c)

Location (Figs. 36, 71): **Pt.c** occupies the caudal sector of the putamen, which is already considerably narrower there and partially infiltrated by fiber masses. The oral part of **Pt.c** is dorsally positioned from **Pt.v**.

C (Fig. 46): Small neurons: Significantly less dense than in case of **Pt.l**, in which respect they are similar to Pt.m. However, regarding dimensions, form and disposition, the small neurons are more similar to those of **Pt.l**. (See Figs. 42-43.)

Large neurons.: Relatively abundant, comparable to **Pt.l**.

M. (Fig. 36): Considerably less rich in medulla than **Pt.l**. Density decrease of the single fibers-network. Otherwise, similar to **Pt.l**.

Putamen ventrale/ ventral putamen (Pt.v)

Topographically and structurally, **Pt.v** represents an intermediate zone between the two putamen nuclei Pt.m. and Pt.l. and the Cauda n. caudati.

Location (Figs. 35, 66-70): **Pt.v** is developed in the caudal half of the putamen, at the point where the tail of the caudate nucleus approaches the putamen once more and fuses with the latter. Located ventrally from **Pt.m** and **Pt.l**, laterally from **Pt.l** (see below) and dorsally from the tail of the caudate nucleus.

C (Fig. 47): Small neurons: Less dense than in **Pt.l**, more dense than in **Pt.m**. Size near-identical with dimensions in **Pt.l**, polygonal or plump-spindle shaped. Quite uniform cell disposition, with minor predominance of the horizontal direction.

Large neurons: Conspicuously few, in particular, as compared with **Pt.l**. The few determinable neurons are generally smaller than in the two dorsal subnuclei.

M (Figs. 48, 35): **Pt.v** appears in much sharper outline, in contrast with the dorsal nuclei in the fiber pattern, especially in contrast with **Pt.l**, than in the cell pattern. Much fewer fine single fibers than in case of **Pt.l**. Rough fibers are hardly present, as in case of **Pt.m**. The fiber bundles located in entirely ventral direction are definitely infiltrating splinter groups of the Türk or Arnold bundle. However, it is not reliably determinable regarding the groups located more dorsally and containing fine and rough fibers, whether these contain eigen-fibers or whether all belong to the Türk bundle.

Putamen limitans/limitans putamen (Pt.li)

A specifically structured zone is found in all primates at the borderline between the putamen and the amygdaloid nucleus. Based on its localization, I intend to name this zone *N. putaminis limitans*. The term *limitans* does not refer here to the structure. In an earlier study (1938), this zone was described as the *Striatum accessorium*.

Location (Figs. 35, 66-68): **Pt.li** is developed in the planes of the caudal amygdaloid nucleus only; it is dorsoventrally limited by **Pt.v** and ventrolaterally by the tail of the caudate nucleus, from which it is sharply separated in all directions. It is always separated from the medially positioned amygdaloid nucleus by a lamella rich in fibers.

C (Fig. 49): Small neurons: Very small, densely positioned (**Pt.li** represents that division of the putamen which contains the smallest and most densely packed cells); rounded to polygonal shape, with narrow, but tigroid-rich protoplasm border.

Large neurons: Still more pronounced reduction of size, as compared with other **Pt** nuclei and as compared with size reduction evident in case of the small neurons. Forms of normal size are occasionally found as well. As compared with **Pt.m** and **Pt.l**, no density reduction is determinable; significantly larger than in **Pt.v**.

Moderately rich in glia.

Figure 51 shows the borderline between **Pt.v** and **Pt.li**, with weaker magnification. A quite sudden structural modification is definitely evident.

M (Fig. 50): In the fiber pattern, **Pt.li** becomes macroscopically prominent due to its abundant fiber content (see Fig. 35). Very dense basal network, but with less dense single fibers network of similar average-fine diameter as in case of **Pt.m** and **Pt.l**, etc. Numerous, mainly sagittally directed, very rough single fibers are additionally present, similar to those found in the fiber pattern located medially from the **Pt.li**, between the Pallidus and the dorsal amygdaloid nucleus. Most of them are presumably infiltrating fibers which - as do numerous fiber bundles - belong to the Arnold bundle.

DISCUSSION OF THE RESULTS

1. A more accurate investigation of the cyto- and myeloarchitectonic striatum structure revealed that this gray - believed to be of mostly uniform structure - consists of a series of variously structured zones. It must be emphasized in this connection that the striatum, as a whole, nevertheless represents a unit of higher order, due to its characteristic uniform structural properties (see p.

15 and following pages, orig. text). Accordingly, the striatum is a true gray as interpreted by C and O. Vogt. Its uniform character is more definitely evident than in the septum gray, for example; in general, the structural differences are not significant. In particular, these do not consist in differences of neurons form and internal structure. Instead, they are merely cytoarchitectonic differences of cell size and cell position; myeloarchitectonically, said differences mainly concern the content of fine, single medullary fibers. Concerning the type and order of magnitude of cytoarchitectonic structural differences, see the text, and in the first place, see the borderline illustrations shown as examples (Figs. 15, 19, 27, 39, 44a. 51). Gurewitsch's contention regarding the equivalence of the striatum subdivisions (determined first by this author) with Brodmann's classification, who divided the brain cortex into fields, should be rejected, because it goes too far - at least until physiologic findings provide convincing proof to the contrary. The anatomical image shows structural differences between individual sectors, which differences are presumably most significantly developed in Man. This could indicate a striatum differentiation with functional reference as well. On the other hand, the order of magnitude of the architectonic differences suggests a largely uniform physiologic function in this area.

Three principal areas were distinguished in the striatum:

- the N. caudatus,
- the Putamen and
- the Fundus striati, which represents the lateral sector of Ziehen's *N. accumbens* in Man. These principal areas do not merely represent topographical units; instead, a definite structural discrimination should be made between them as well.

It was found that the three principal zones had no uniform structural features either. The extensive fundus, in particular, shows far-reaching divisions. Table 52 displays the additional divisions of the striatum. Besides zones including the three main nuclei, two zones located in the immediate vicinity of the fundus can also be defined as belonging to the striatum. These represent specific cases from several viewpoint within the entire pattern and were described accordingly. They are:

- the Insulae olfactoriae striatales (Calleja) and possibly
- the N. subcaudatus (see Table).

2. When investigating and comparing the structure of various fundus nuclei and the adjacent caudate nucleus and putamen structures, it often appears as if a specific serial correlation existed between these structures (see Fig. 14-18). **Figure 52** includes a diagrammatic representation of these conditions: the somewhat large-celled *Fundus subventricularis lateralis* follows after the *Fundus subventricularis medialis*, characterized by very small and dense cells. Subsequently, the series (which is uniform so far) divides, proceeding on the one hand, over the *Fundus caudati* to the caudatus, while cell size and differentiation increases; on the other hand., it reaches the putamen over the *Fundus putaminis*. This phenomenon is very similar to conditions prevailing the island cortex (Brockhaus, 1940) in the subcortical zone. In the Nissl and Weigert staining, the striatal "differentiation sequence"⁷ - in contrast to that of the insular cortex - seems to indicate that these united areas (direction of the arrow in **Fig. 52**) progress in parallel to the ontogenetic differentiation level. The specified example of the insular differentiation sequence indicates that the aforementioned development as such has nothing in common with the conception of the differentiation series; instead, we are merely faced here with a characteristic of the striatal (series). In that

⁷ The definition "differentiation sequence" is used instead of the definition "differentiation direction" used in the cited study because it refers to a quite specific phenomenon in evolutionary mechanics.

case, we could refer, at the most, to a phylogenetic elevation development (*Höherentwicklung*) of the cortex characteristic, while assuming that the allogenetic fields which form the starting point of the series (at variance from the meso- and isocortical fields) represent a phylogenetically more ancient stage. It cannot be readily confirmed (on the basis of the Nissl pattern which seems to indicate less differentiated areas in the fundus nuclei) that the functional level (*Funktionshöhe*) is lower, as compared with the "higher" levels of differentiation of the caudate nucleus and of the putamen. In the first place, the confirmation of the low ontogenetic differentiation requires additional investigations with other histologic methods; secondly, it is quite possible that these zones reached an optimal morphologic and physiologic differentiation grade, suitable for their specific functions, even if said grade might be "lower" as compared with other zones.

3. In literature - principally in comparative anatomic literature - components corresponding to the *N. accumbens* of the striatum (see p. 15 and 17 of German text) are repeatedly correlated with the sense of smell, as the so-called "olfactory striatum". Insofar as an opinion can be formed regarding the above on the basis of standard anatomic investigations, findings indicate that this is presumably correct concerning the *Insulae olfact. striatales* (probable fiber links, structural characteristics). Whether and how far fundus components are involved in this functional complex cannot be decided.

Man and the higher apes show only quite rudimentary remnants of the cortex formation corresponding to the true cortex of the olfactory tubercle found in macrosomatics. These remnants are certainly no longer functional. The participation (in macrosomatics) of said cortex (defined by comparative anatomy as the "Tuberculum olfactorium") in the olfactory function has been confirmed. However, since this area almost vanished in Man and in the higher apes, the olfactory tubercle of the microsomatics and

macrosmatics can in no way be defined as functionally identical. It seems highly unlikely that the striatum tissue (fundus) (which replaces the "olfactory cortex") assumed the function of the vanished cortex. The following fact, among other, disproves such an interpretation of the fundus as "olfactory striatum": the absolute and relative dimensional evolution and differentiation of the *Fundus striati* in microsmatics, especially in Man, increased, rather than decreased. The dimensional increase (according to Johnston's contention) of the "head of the caudate nucleus" in macrosmatics refers to studies in *Lemur catta*, in the dog, rabbit, mouse and Didelphys. These studies mainly show the medial, large-cell component of the *N. accumbens*, the rudimentary remnants of which were incorporated in Man in the *Ins. olf. striat.*; while in macrosmatics the true fundus area shows no such dimensional increase. Moreover, the structural cotrelations of specific subnuclei in the fundus (diagrammatically shown in Fig. 52) also speak in favor of close links - possibly in the functional field as well - with the caudate nucleus and the putamen, while, in principle, no functional separation from the latter seems to exist. Summarizing: it can be stated on the basis of standard architectonical investigations that the "olfactory component" of the striatum in Man is probably restricted to the large-cell components of the *Insulae olfactoriae striatales*; it can be stated on the other hand: the possibility should not be excluded that olfactory stimuli reach the *Fundus striati* as well.

The correlation between fibers and the *Stria terminalis* or any structural affinity with the gray substance surrounding the oral termination of this bundle probably prompted Johnston (1923) to define the entire zone at issue here as "the bed of the stria terminalis." I was unable to confirm the above, nor was Kodama able to do so.

4. The differentiation described here, based on standard architectonics, could provide no anatomic basis for the somatotopic system derived from the classification of clinical symptoms and from the localization of pathologic-anatomic alterations

[Mingazzini, C. and O. Vogt, A. Jakob and recently: Hassler (1939)]. Apart from the smaller, ventrally and caudally located putamen nuclei, the caudate nucleus as well as the putamen are divided into two larger units (**Cd.m** and **Cd.l**, as well as **Pt.m** and **Pt.l**). The location (see Fig. 36) as well as the varied distribution of the fiber bundles seem to indicate that the position of the individual zones in the conduction system varies, to some extent, i.e., **Pt.m** and **Cd.l** are closer to the pallidum, while **Pt.l** and **Cd.m** are farther from the latter.

SUMMARY

1. The cyto- and neuroarchitectonics of the septum gray and of the striatum was accurately investigated. Several nuclei were defined and specified in both zones.

a) These were, in the septum gray:

1. The N. septoventricularis,
2. The N. septofornicatus, with a dorsal (Sf.d), a ventrolateral (Sf.v.l) and a ventrocaudal (Sf.v.c) subnucleus,
3. the N. interfornicatus septi,
4. the N. parvocellularis septi.

Among fiber patterns, merely the intersection (poor in fibers) ventrocaudally from the *Fornix inferior* was specified as *Com. subfornicalis*; it corresponds to the intersection defined earlier by O. Vogt as the *Psalt. ventrale orale*.

b) In the striatum, at variance from the customary division into two units (N. caudatus, putamen), three main nuclei were specified (*Fundus striati*, *N. caudatus*, *putamen*); these form topographically as well as structurally dissimilar units; all were also divided into several subnuclei (see Table).

Table

Striatum		Fu	Fundus striati											
				<table border="1"> <tr> <td>Fu.</td> <td>Fu. subventricularis med.</td> </tr> <tr> <td>Fu.sv.l</td> <td>Fu. subventricularis lat.</td> </tr> <tr> <td>Fu.cd</td> <td>Fu. caudati</td> </tr> <tr> <td>Fu.pt</td> <td>Fu. putaminis</td> </tr> </table>	Fu.	Fu. subventricularis med.	Fu.sv.l	Fu. subventricularis lat.	Fu.cd	Fu. caudati	Fu.pt	Fu. putaminis		
Fu.	Fu. subventricularis med.													
Fu.sv.l	Fu. subventricularis lat.													
Fu.cd	Fu. caudati													
Fu.pt	Fu. putaminis													
		cd	N. caudatus											
				<table border="1"> <tr> <td>Cd.m</td> <td>Caud. medialis</td> </tr> <tr> <td>Cd.l</td> <td>Caud. lateralis</td> </tr> </table>	Cd.m	Caud. medialis	Cd.l	Caud. lateralis						
Cd.m	Caud. medialis													
Cd.l	Caud. lateralis													
		pt	Putamen											
				<table border="1"> <tr> <td>Pt.m</td> <td>Put. mediale</td> </tr> <tr> <td>Pt.l</td> <td>Put. laterale</td> </tr> <tr> <td>Pt.v</td> <td>Put. ventrale</td> </tr> <tr> <td>Pt.c</td> <td>Put. caudale</td> </tr> <tr> <td>Pt.li</td> <td>Put. limitans</td> </tr> </table>	Pt.m	Put. mediale	Pt.l	Put. laterale	Pt.v	Put. ventrale	Pt.c	Put. caudale	Pt.li	Put. limitans
Pt.m	Put. mediale													
Pt.l	Put. laterale													
Pt.v	Put. ventrale													
Pt.c	Put. caudale													
Pt.li	Put. limitans													
		I.o.s	Insulae olfact. striatales											
		sc	Ncl. subcaudatus											

The *Fundus striati* is characterized by the well-defined "gradation" of its subnuclei. Starting from the medial subventricular subnucleus, the dimensions and differentiation of the neurons increase gradually while cell density decreases, resulting in a "differentiation series" in each case relatively to the medial subnucleus of the N. caudate nucleus and putamen.

The division applied to the caudate nucleus and putamen cannot be considered as the morphologic basis (relatively to pathologic-anatomic diagnoses) for the somatotopic analysis of the striatum, as assumed by numerous investigators. No confirmation was found for the above according to normal structural conditions.

2. Despite specific divisions, the septum gray, as well as the striatum, must be regarded as architectonic units of a higher order. The uniform character in the striatum is structurally more pronounced than in the septum gray.
3. No closer structural correlation exists between the striatum or the individual parts (fundus) and the septum gray.

REFERENCES

- Beccari, N., La sostanza perforata anterior e i suoi rapporti col rinencefalo etc. Arch. ital. Anat. 9. 1910.
- Beck, E., Morphogenie der Hirnrinde. Berlin 1940.
- Bielschowsky, M., Einige Bemerkungen zur normalen und pathologischen Histologie des Schweif- und Linsenkerns. J. Psychol. u. Neur. 25. 1919.
- Brockhaus, H., Zur normalen und pathologischen Anatomie des Mandelkerngebietes. J. Psychol. u. Neur. 49. 1938.
- Brockhaus, H., Die Cyto- und Myeloarchitektonik des Cortex claustralis beim Menschen. J. Psychol. u. Neur. 49. 1940.
- Brunner, H., Beiträge zur Histologie des menschlichen Bulbus olfactorius. Z. Hals- usw. Hk. 6. 1923.
- Cajal, S. Ramon Y., 1904. Zit. nach Herrick.
- Calleja, C., La region olfactoria del cerebro. Madrid 1893.
- Crosby, E. C., The forebrain of Alligator mississippiensis. J. comp. Neur. (Am.) 27. 1917.
- Crosby, E. C. und Humphrey, T., Studies of the vertebrate Telencephalon. I. Olfactory and access. olf. nucleus. J. comp. Neur. (Am.) 71. 1938.
- Dart, R. A., A contribution to the morphology of the Corpus striatum. J. Anat. (Brit.) 55. 1920.
- Gurewitsch, M., Cytoarchitektonische Gliederung des Neostriatum der Säugetiere. Z. Anat. 93. 1930.
- Hassler, R., Zur pathologischen Anatomie des senilen und des parkinsonistischen Tremors. J. Psychol. u. Neur. 49. 1939.
- Herrick, C. J., The morphology of the forebrain in Amphibia and Reptilia. J. comp. Neur. (Am.) 20. 1927.
- Herrick, C. J., The nucleus olfactorius anterior of the opossum. J. comp. Neur. (Am.) 37. 1924.
- Herrick, C. J., The Amphibian Forebrain. IV. J. comp. Neur. (Am.) 43. 1927.
- Hochstetter, F., Beiträge zur Entwicklungsgeschichte des menschlichen Gehims. Teil I. Wien und Leipzig 1919.
- Johnston, J. B., The morphology of the septum, hippocampus and pallial commissures in reptiles and mammals. J. comp. Neur. (Am.) 23. 1913.
- Johnston, J. B., The cell masses in the forebrain of the turtle, Cistudo Carolina. J. comp. Neur. (Am.) 25. 1915.
- Johnston, J. B., Further contributions to the study of the evolution of the forebrain. J. comp. Neur. (Am.) 35. 1923.
- Kappers, A., Vergleichende Anatomic des Nervensystems. II. Teil. Haarlem 1921.
- Kappers, C. 13. und Theunissen, W. F., Die Phylognese des Rhinencephalon, des Corpus striatum und der Vorderhirnkommissuren. Fol. neurobiol. (D.) 1. 1908.
- Kodama, S., Über die sogenannten Basalganglien. II. Schweiz. Arch. Neur. 19. 1926.
- Kryspin-Exner, W., Vergleichend anatomische Studien über die Substantia perforata anterior der Säugetiere. Obersteiners Arb. 23. 1922.
- Loo, Y. T., The Forebrain of the opossum, Didelphis virginiana. J. comp. Neur. (Am.) 51. 1931.
- Meynert, Th., Vom Gehirn der Säugetiere. Strickers Handb. d. Lehre von den Geweben usw. Leipzig 1872.
- Röthig, P., Riechbahn, Septum und Thalamus bei Didelphys marsup. Abh. Senckenberg. naturf. Ges., Frankf. M. 1909.
- Röthig, P., Beiträge zum Studium des Zentralnervensystems der Wirbeltiere. V. Verh. Kon. Acad. van Wetensch. Amsterdam 17, 1. 1912.
- Rose, M., Über d. histogenetische Prinzip d. Einteilung d. Großhirnrinde. J. Psychol. u. Neur. 32. 1926.
- Rose, M., Die sog. Riechrinde beim Menschen und beim Affen. J. Psychol. u. Neur. 34. 1927.
- Rose, M., Cytoarchitektonik und Myeloarchitektonik der Großhirnrinde. Bumke-Förster, Handb. d. Neurol., Bd. I. Berlin 1935.
- Shimazono, Das Septum pellucidum des Menschen, Arch. Anat. u. Physiol., Anat. Abt. 1912.

- Smith, G. Elliot, On the morphology of the cerebral commissures in the Vertebrata etc. Trans. Linn. Soc. London, 2 ser. Zool. 8. 1903. Zit. nach Herrick.
- Smith, G. Elliot, A preliminary note on the morphology of the Corpus striatum and the origin of the neopallium. J. Anat. (Brit.) 53. 1919.
- Spiegel, E., Die Kerne im Vorderhirn der Säuger. Obersteiners Arb. 2., 426. 1919.
- Vogt, C., Quelques considérations générales à propos du syndrome du corps strié. J. Psychol. u. Neur. 18. 1911.
- Vogt, C. und O., Nouvelle contribution à l'étude de la myéloarchitecture de l'écorce cérébrale. XX. Congrès des médecins aliénistes et neurol. de France. Bruxelles 1911.
- Vogt, C. und O., Allgemeinere Ergebnisse unserer Hirnforschung. J. Psychol. u. Neur., 25, Erg.-H. 1. 1919.
- Vogt, C. und O., Zur Lehre der Erkrankungen des striären Systems. J. Psychol. u. Neur. 25, Erg.-H. 3. 1920.
- Vogt, C. und O., Sitz und Wesen der Krankheiten im Lichte der topistischen Hirnforschung usw. J. Psychol. u. Neur. 47. 1937.
- Vogt, O., Über Fasersysteme in den mittleren und caudalen Balkenabschnitten. Neur. Zbl. 1895.
- Winkler, C., Sur l'évolution du corps strié. Rev. neur. (Fr.) 37. 1930.
- Winkler, C. und Potter, A., An Anatomical Guide to Experimental Researches on the Cat's Brain. Amsterdam 1914.
- Ziehen, Th., Das Zentralnervensystem der Monotremen und Marsupialier. II, 2. Denkschr. d. med.-naturw. Ges. zu Jena 6. 1908.

FIGURES

- Fig.1. Survey of the septum gray in the cellular pattern. A 43 r 4 267. X 30 : I.Ph 21491.
- Fig.2. Survey of the septum gray in the fiber pattern (Weigert-Kutschitzky staining). A 28 r 4 3185. Magnification 5 : 1. Ph. 22955.
- Fig.3. Nucleus septoventricularis (see Fig. 1). A 43 r 4 265; Magnification 200:1. Ph. 22661.
- Fig.4. N. septofornicatus ventroralis (see Fig. 1). A 43 r 4 267. Magnification: 200 : 1. Ph. 22661.
- Fig.5. N. septofornicatus ventrocaudalis. A 43 r 4. Magnification: 200 : 1. Ph. 22891.
- Fig.6. N. septofornicatus dorsalis. A 43 r 4 246. Magnification: 200 : 1 Ph 22890.
- Fig.7. N. interfornicatus septi (see Fig. 62). A 58 r 3 1424. Magnification: 200 : 1. Ph. 22774.
- Fig.8. Same nucleus as it Fig. 7, between Fornix fiber bundles. A 58 r 3 1334. Magnification: 200 : 1. Ph 22892.
- Fig.9. The subfornical commissura in the frontal section. A 58 r 3 1204. Magnification 30 : 1. Ph. 22886.
- Fig.10. The subfornical commissura in the horizontal section. A 66 r 3 659. Magnification 30 : 1. Ph. 22885.
- Fig.11. N. parvocellularis septi (see Fig. 1). A 43 r 4 265. Magnification. 200 : 1. Ph. 22776.
- Fig.12. Survey of the striatum in the fiber pattern. The limits were indicated by using the cellular pattern (Section 724). A 61 r 3 727/28. Magnification. 3 : 1. Ph. 22958.
- Fig.13. Survey of the Fundus striati nuclei adjoining the ventricle (see Fig. 59 in original text). A 58 r 3 1554. Magnification: 30 : 1 Ph. 21487.

- Fig.14. Top: Fundus subventricularis medialis; bottom: Fundus subventricularis lateralis. Numerous average-sized spindle cells in the intermediate subependymal glia band. (Position: compared with Fig. 60 of original text) A 58 r 3 1498. Magnification. 200 ; 1. Ph. 22824.
- Fig.15. The boundary between the Fundus subventricularis medialis (right) and lateralis (left), more ventrally located than in Fig. 14 (see Fig. 59). A 58 r3 1554. Magnification 100 : 1. Ph. 22808.
- Fig.16: Fundus subventricularis lateralis (see Fig. 59). A 58 r 3 1554..Magnification 200 : 1. Ph, 22784.
- Fig.17: Fundus caudati (see Fig. 55). A 58 r 2 395. Magnification 200 : 1 Ph. 22889.
- Fig.18: Fundus putaminis (see Fig. 59). A 58 r 3 1554. Magnification 200 : 1. Ph. 22785.
- Fig.19: The boundary between the Fundus subventricularis lateralis (right) and the Fundus putaminis (left) (see Fig. 59). A 58 r 3 1554. Magnification 100 : 1. Ph. 22807.
- Fig.20: Fundus subventricularis lateralis (top) and Fundus putaminis (bottom) in the fiber pattern. (Weigert-Kultschitz staining). A 371 2327. Magnification 100 : 1. Ph. 22817.
- Fig.21: Position of the embryonal olfactory ventricle and its matrix layer (from Hochstätter, 1919).
- Fig.22: Various groups of Insulae olfactoriae striatales. The arrows indicate large striatum cells (for localization, see Fig. 60). A 58 r 3 1498. Magnification 100 : 1. Ph. 22819.
- Fig.23: The rudimentary remnants of the Area tuberculi olfactorii lateralis (see also text). A 43 r 4 26 7. Magnification 50 : 1. Ph. 23026.
- Fig.24: The human rudimentary remnant of the Area tuberculi olfactorii medialis (see also text). A 58 r 3 1535. Magnification 50 : 1.. Ph. 23023.
- Fig.25: N. subcaudatus (see Fig. 62). A 58 r 3 1397. Magnification 200 : 1. Ph. 22691.
- Fig.26: N. subcaudatus. A 371 2297. Magnification: 100 : 1. Ph. 22813.
- Fig.27: The boundary between the N. caudate nucleus(right) and the putamen (left) in a cell bridge of the internal capsula (see Fig. 63). A 58 r 3 1101. Magnification 100 : 1. Ph. 22804.
- Fig.28: N. caudate medialis (see Fig. 55). A 58 r 2 395. Magnification: 200 : 1. Ph. 22888.
- Fig.29: N. caudatus lateralis, from the same section as shown in Fig. 28. A 58 r 2 395. Magnification: 200 : 1. Ph. 22887.
- Fig.30: Segment of the ventricle border zone of the N. caudatus medialis (see Fig. 60). A 58 r 3 1476. Magnification: 30 : 1. Ph. 21502.
- Fig.31: Cauda n. caudati (see Fig. 67). A 58 r 3 900. Magnification: 200 : 1. Ph. 22822.
- Fig.32: Cauda n. caudati (set Fig. 35). A 371 2000. Magnification: 100 : 1. Ph. 22816.
- Fig.33: N. caudatus medialis. A 371 2321. Magnification: 150 : 1. Ph. 22830.
- Fig.34: N. caudatus lateralis, same section as in Fig. 33. A 371 2321. Magnification: 150 : 1. Ph. 22829.
- Fig.35: General view showing the subnuclei of the putamen in the frontal section (Weigert-Kultschitzky staining). A 371 2012. Magnification: 3 : 1. Ph. 22956. Above the numeral 40, the indication should be Pb.m instead of Pt.m.
- Fig.36: General view showing the nuclei of the striatum in the horizontal section. The borderlines were entered while controlling the cellular pattern (Hematoxylin-Heidenheim staining). A 66 r 3 398. Magnification: 3 : 1. Ph. 22957.
- Fig.37: Putamen mediate (see Fig. 59). A 58 r 3 1554. Magnification: 200 : 1. Ph. 227 3.
- Fig.38: N. caudatus medialis, for comparison with Fig. 37; same section. Ph. 22748.
- Fig.39: The borderline between the Putamen mediate (top) and the Fundus subventricularis (bottom). Location: see Fig. 60. A 58 r 3 1498. Ph. 22806.

Fig.40: Putamen mediale (Weigert-Kultschitzky staining). See Fig. 35. The rough single fibers - left top - and the rough Fb are clearly discernible; the fine fibers are, not dissolved in the Fb and appear as uniform gray surfaces.

Fig.41: Putamen mediale. Due to stronger differentiation, the fine fibers stain substantially paler. As a result, the rough fibers become more prominent. A 3712330. Magnification: 150 : 1. Ph. 22828.

Fig.42: Putamen laterale (see Fig. 65). A 58 r 3 1101 Magnification: 200 : 1. Ph. 22782.

Fig.43: Putamen mediale. For comparison, see Fig. 42, same section. Ph. 22781.

Fig.44: Borderline between the Putamen mediale (right) and laterale (left) a) in the cellular pattern, and b) in the fiber pattern. See text on the formation of the borderline. a) (see Fig. 66). A 58 r 3 1000. Magnif.: 100 : 1. Ph. 22819, b) (see Fig. 35). A 3712012. Magnif.: 50 : 1. Ph. 23091.

Fig. 45: Putamen laterale. Same section as in Fig. 40. (Position as in Fig. 35.) A 3712012. Magnification: 150 : 1. Ph. 22826.

Fig.46: Putamen caudale (see Fig. 71). A 58 r 3 501. Magnification: 200 : 1. Ph. 22823.

Fig.47: Putamen ventrale (see Fig. 67). A 58 r 3 900. Magnification: 200 : 1. Ph. 22953.

Fig.48: Putamen ventrale (see Fig. 35). A 3712000. Magnification: 100 : 1. Ph. 22815.

Fig.49: Putamen limitans (see Fig. 67). A 58 r 3 950. Magnification: 200 : 1. Ph. 22790.

Fig.50: Putamen limitans (see Fig. 35). A 3712000. Magnification: 100 : 1. Ph. 22814.

Fig.51: Borderline between the Putamen ventrale (left) and limitans (right). For localization, see Fig. 67. A 58 r 3 900. Magnification: 100 : 1. Ph. 22821.

Fig.52: Diagrammatic representation of the differentiation series in the striatum. See text.

Figs.53-71: Diagrams of A 58: frontal series. Magnification approx. 2.3 : 1. The outlines of the nuclei in the fiber pattern were designed with the Abbe drawing apparatus; magnification 3 : 1; the borderlines, as seen under the microscope, were mostly entered according to photographic surveys of adjoining sections, stained according to Nissl.

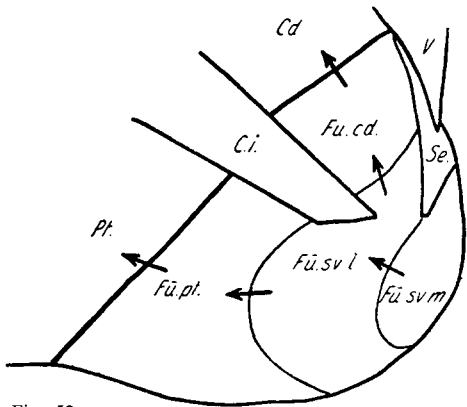


Fig. 52.

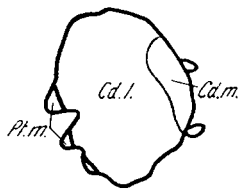


Fig. 53. A 58 r 2 604

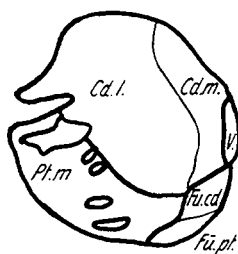


Fig. 54. A 58 r 2 503

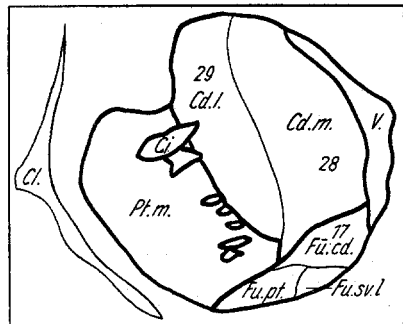


Fig. 55. A 58 r 2 394

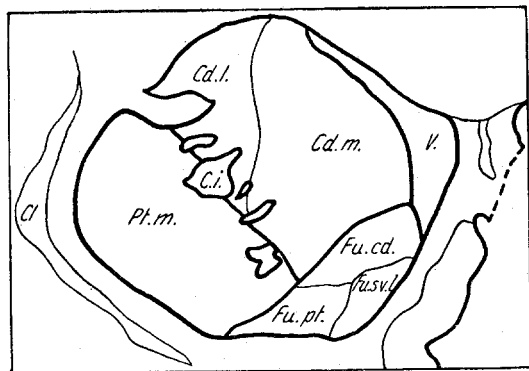


Fig. 56. A 58 r 2 300

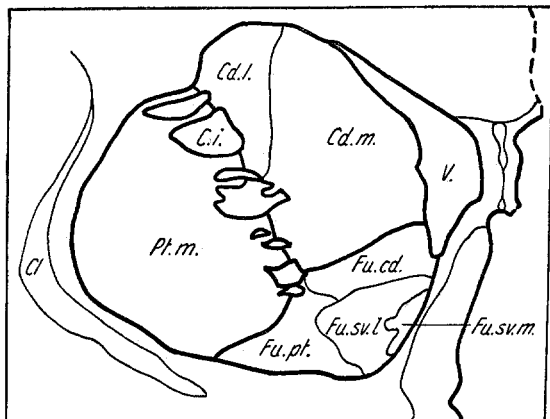


Fig. 57. A 58 r 2 200

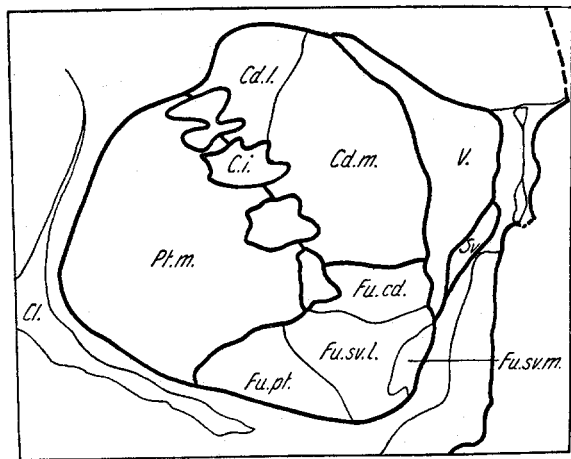


Fig. 58. A58 r2 102

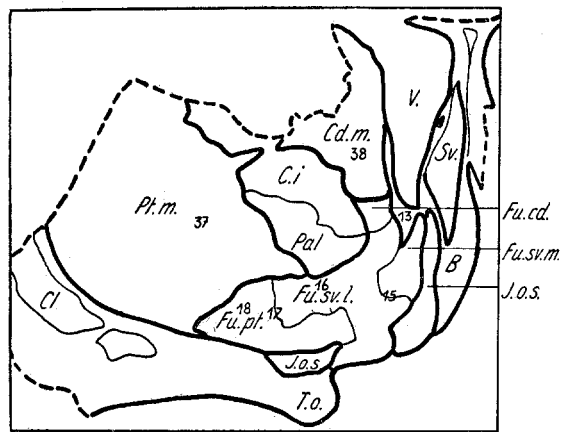


Fig. 59. A58 r3 1555

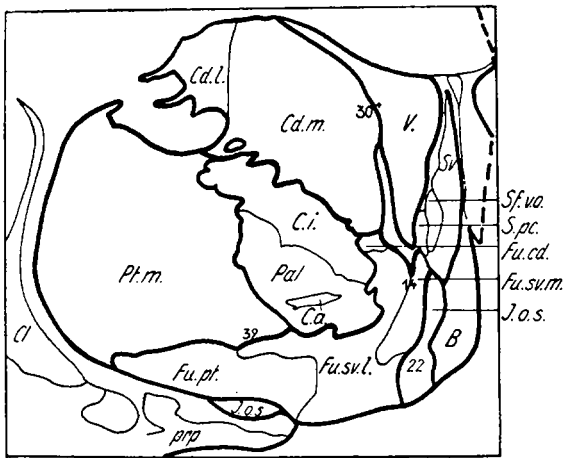


Fig. 60. A 58 r 3 1499

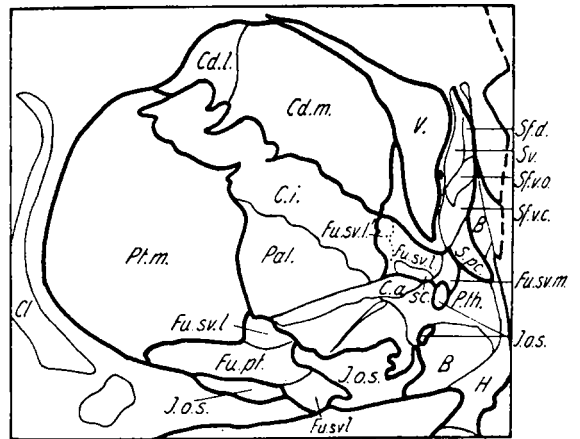


Fig. 61. A 58 r 3 1449

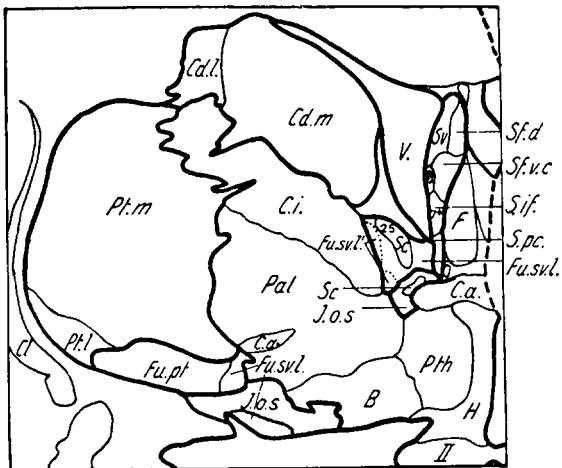


Fig. 62. A 58 r 3 1398

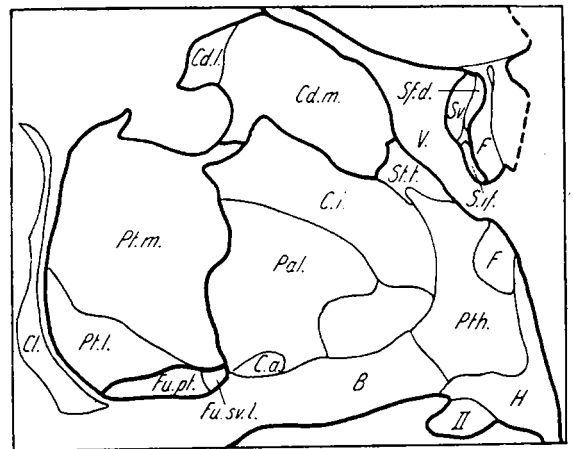


Fig. 63. A 58 r 3 1302

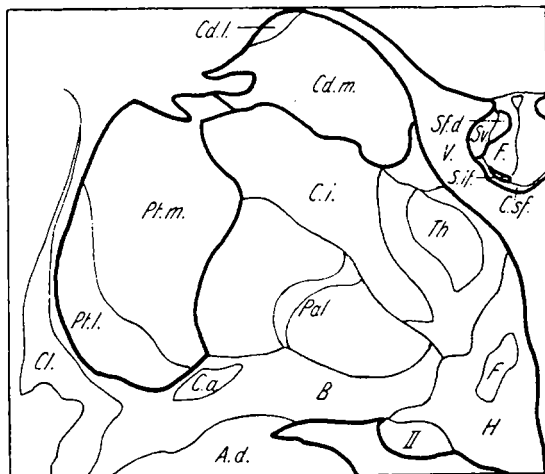


Fig. 64. A 58 r 3 1204

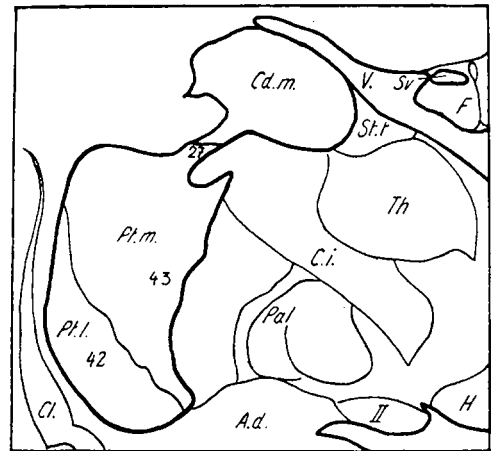


Fig. 65. A 58 r 3 1102

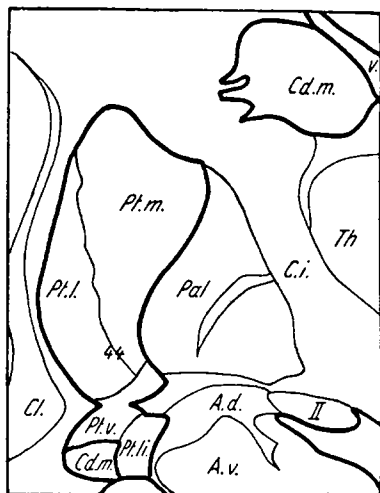


Fig. 66. A 58 r 3 1001

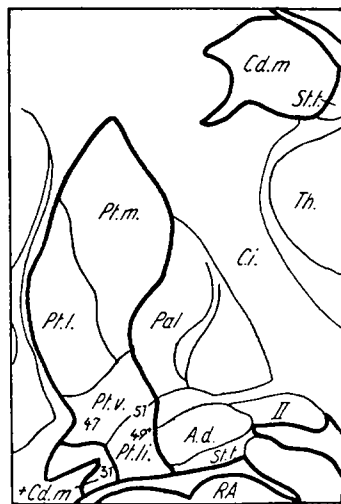


Fig. 67. A 58 r 3 901

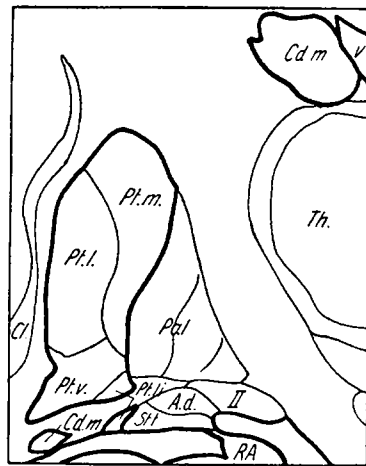


Fig. 68. A 58 r 3 795

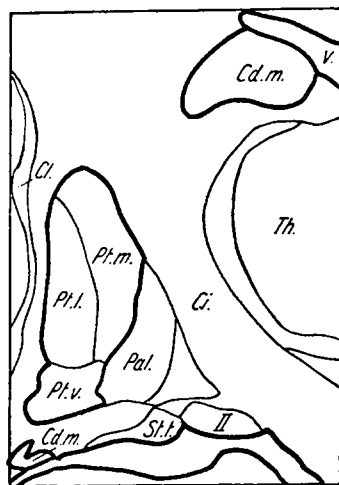


Fig. 69. A 58 r 3 701

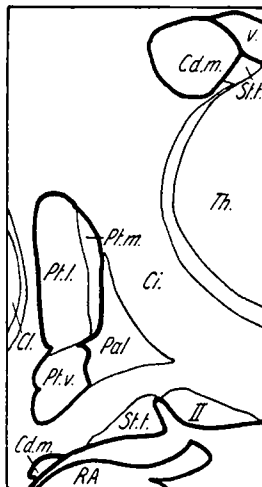


Fig. 70. A 58 r 3 605



Fig. 71. A 58 r 3 504